

Traumatic Thoracolumbar Fx β-Launch Presentation

Principle Investigators: Craig Birch & Daniel Hedequist

Coordinators: Jack Kriz & Saurav Pandey

Program Manager: Fernanda Canizares

March 3rd 2026



Background

- **No pediatric-specific standard** of care for thoracolumbar (TL) spine trauma; most management **extrapolated from adult literature**
- Pediatric anatomy, growth potential, and biomechanics differ from adults
- Lack of consensus regarding:
 - Surgical indications
 - Extent of fusion
 - Operative approach
- Regional institutional practice variation and potential specialty-based variation (orthopaedic vs neurosurgery)
- Goal: Greater standardization, consistency of care, and improved outcomes

Primary Aim

To determine the most frequent fracture patterns and associated treatment characteristics, and to compare intraoperative outcomes across injury and treatment variations, for pediatric thoracolumbar (TL) spinal trauma treated at CORTICES institutions.

Hypothesis: The most common fracture pattern in pediatric thoracolumbar trauma will be burst-type fractures, with posterior spinal fusion spanning two levels above and below the injured segment as the predominant surgical treatment across institutions.

Secondary Aims

#1: To estimate frequency of reoperation and determine most common complications following spinal surgery for TL trauma in pediatric patients treated across CORTICES institution.

Hypothesis: Pediatric patients undergoing spinal surgery for thoracolumbar trauma will have a low rate of reoperation and implant related issues will be the most common complications following spinal surgery for TL trauma.

#2: To determine regional and surgeon-specific differences in surgical management of pediatric thoracolumbar trauma, including treating surgeon specialties and surgical approaches, across CORTICES institutions.

Hypothesis: There will be significant differences in the surgical management with variation in both regional treatment patterns and surgeon-specific practices, particularly regarding whether the treating surgeon is from Orthopedics or Neurosurgery.

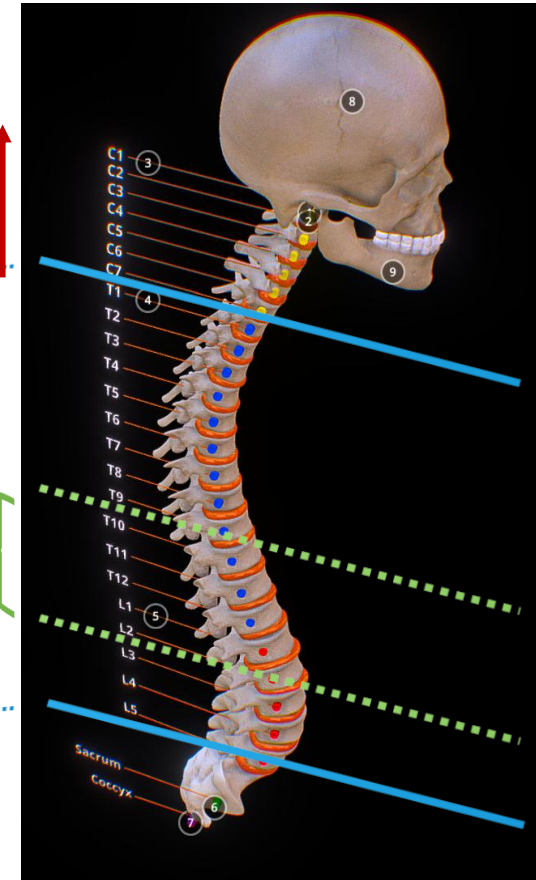
Study Specific Definition: TL Zone

- Traditional thoracolumbar (TL) region conceptualized as “transition zone” from **T10 – L2**
- For this study, we define thoracolumbar region of the spine as any component of the **Thoracic or Lumbar** region **T1 – L5**.
 - Fractures extending **cervicothoracic junction** excluded
 - Fractures extending **lumbosacral junction** included, given proximity to the TL transition zone and similar biomechanical considerations

Study Definition
Zone

TL
Transition Zone

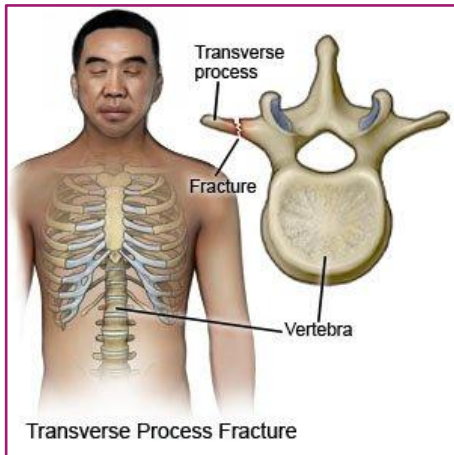
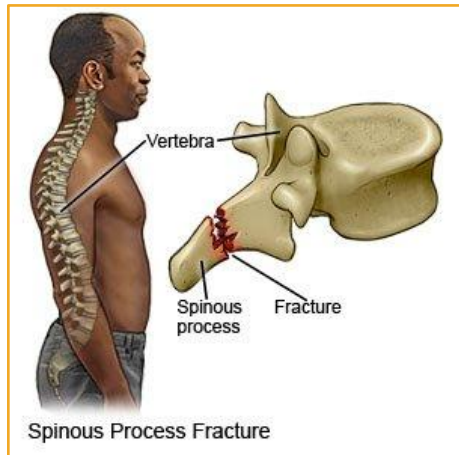
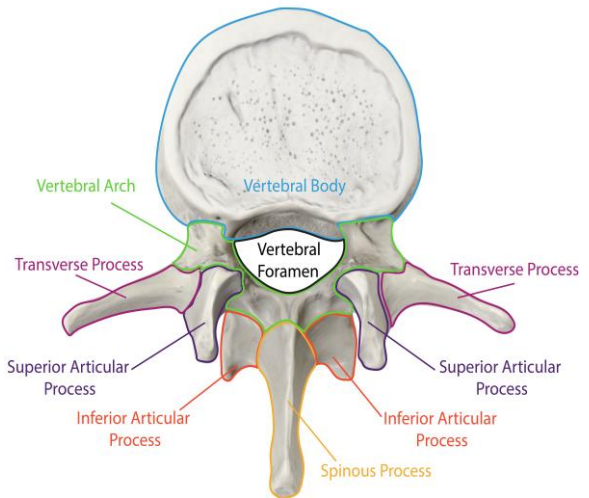
Exclude



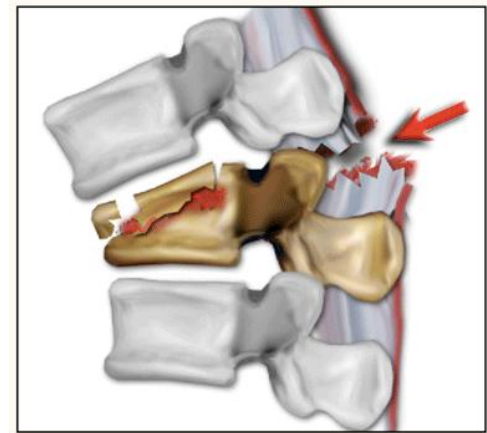
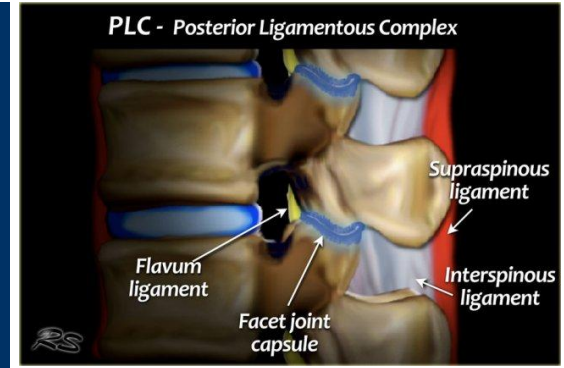
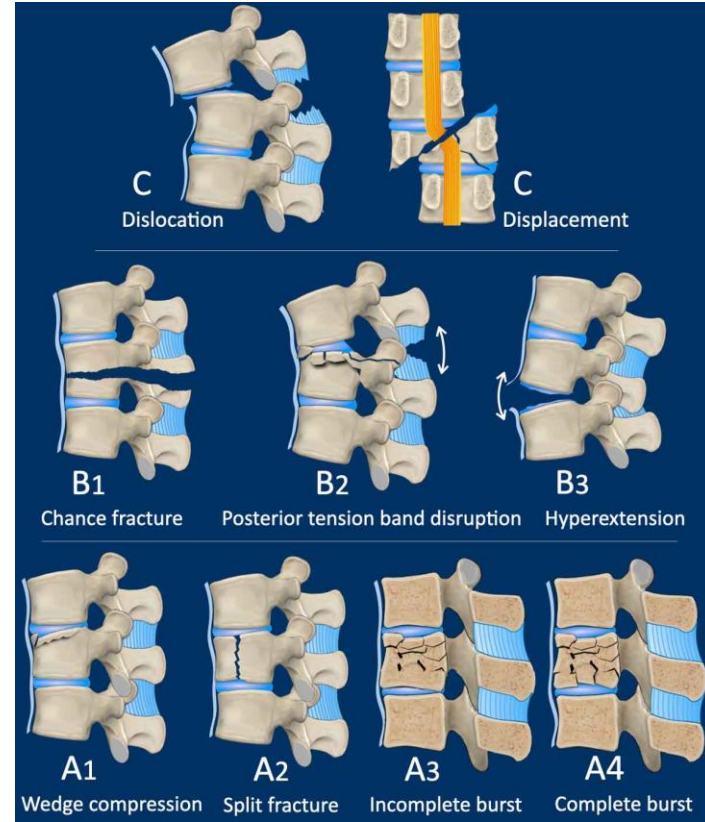
ID	VERTEBRAL BODIES	TRANSITION ZONE	STUDY ZONE	INCLUDE?
1	T3, T4, T5	NO	YES	✓
2	C7, T1	NO	NO	✗ C7 extends zone
3	T12, L1, L2	YES	YES	✓
4	L5, S1	NO	YES	✓



Minor Injuries: Managed Non-Op (Exclude)



Major Injuries: Managed Operatively (Include)



Inclusion & Exclusion Criteria

Inclusion

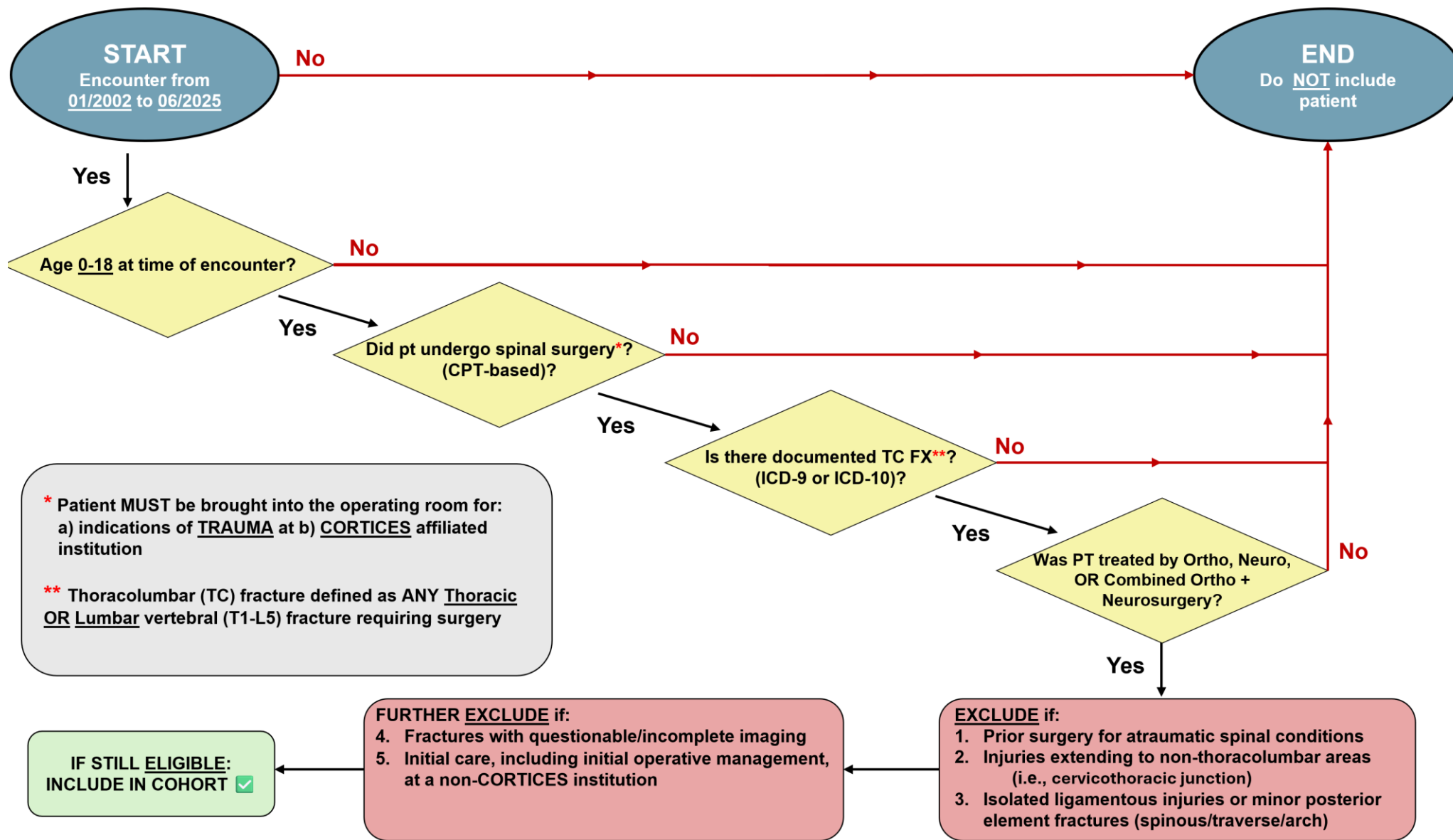
- Pediatric patients aged 0 to 18.99 years at presentation.
- Patient who underwent spinal surgery for thoracolumbar (TL)* spinal trauma at CORTICES institutions between January 2002 and June 2025.
- Patients treated by Orthopaedics, Neurosurgery, or a combined Orthopaedic/Neurosurgery procedure

*TL Vertebral Levels = T1 – L5

Exclusion

- Underlying atraumatic spinal conditions that required prior surgery
- Fracture extending to non-thoracolumbar regions (i.e., cervicothoracic junction)
- Spinal injuries such as contusion or distortion, exclusive ligamentous injuries, or isolated fractures of the spinous/transverse processes, and the vertebral arch
- Questionable fractures without clear radiologic evidence and/or incomplete radiological documentation
- Fractures initially treated at an external hospital not part of CORTICES.

Flow Diagram



Data Codes

CPT Codes: 22556; 22610; 22612; 22630; 22633; 22800; 22802; 22804; 22842; 22843; 22844; 63003; 63016; 63042; 63046; 63047; 63055; 63056; 63057; 63064

ICD Codes:

ICD-10

S22.0: Fracture of thoracic vertebra (S22.00 – S22.08)

S32.0: Fracture of lumbar vertebra (S32.00 – S32.05)

S24.1: Other and unspecified injuries of thoracic spinal cord (S24.10; S24.11; S24.15)*

S34.1: Other and unspecified injury of lumbar and sacral spinal cord (S34.10; S34.11; S34.12)*

ICD-9

805: Fracture of vertebral column without mention of spinal cord injury (805.2 – 805.5; 805.8*; 805.9*)

806: Fracture of vertebral column with spinal cord injury (806.2 – 806.5; 806.8*; 806.9*)

** May capture cases related to spinal cord, but not spine itself. Please use discretion*



Boston
Children's
Hospital



HARVARD
MEDICAL SCHOOL

CORTICES

ADVANCING EVIDENCE-BASED ORTHOPEDIC CARE

Identifying Patient Cohort

“Ideal” Cohort Pull

- Query CPT codes for TL spine surgery
- Cross-reference with ICD-9/10 diagnosis codes for thoracic and/or lumbar spine fracture
- CPT code + relevant ICD pairing should capture operative TL trauma cases
- Designed to efficiently identify eligible patients at each institution

How Lead Site Found Patients

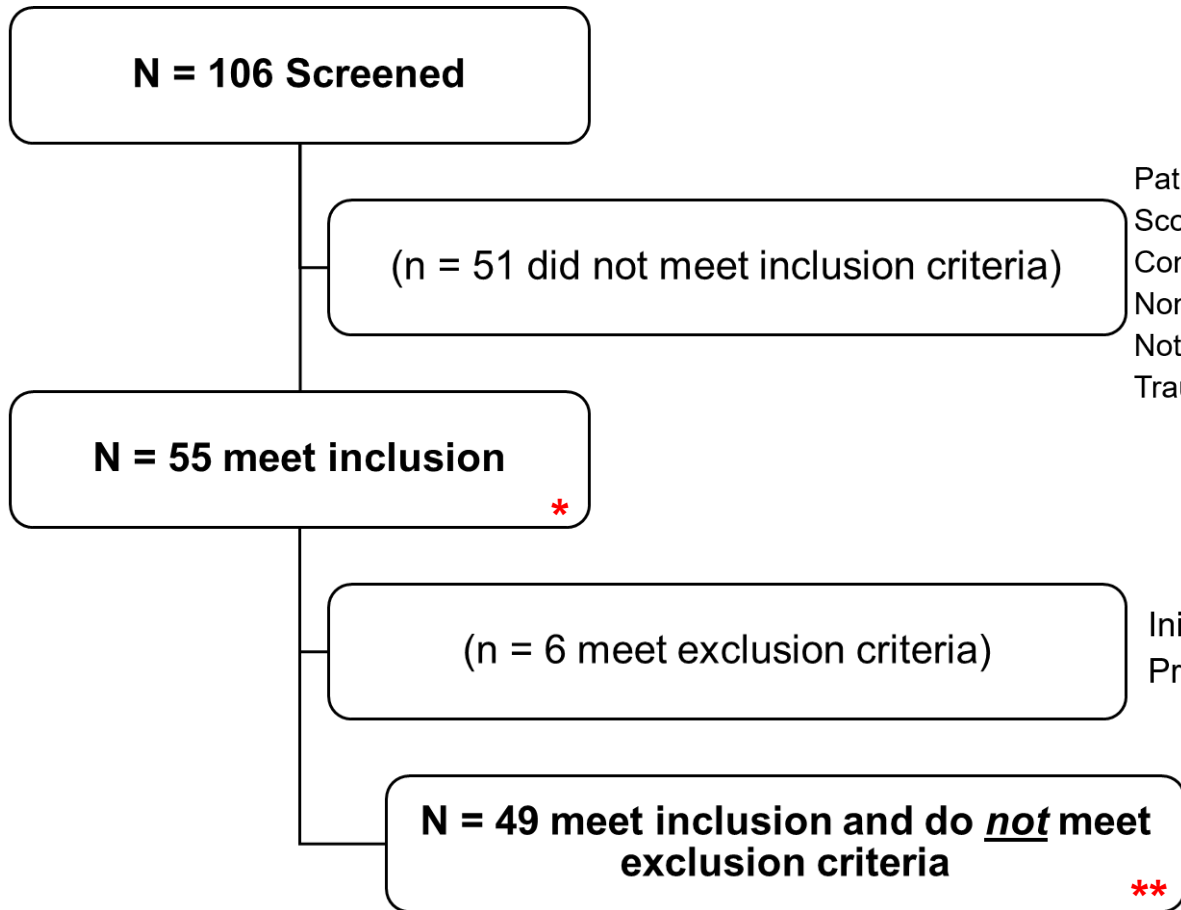
Initial CPT-based query yielded high volume non-traumatic cases (pathologic fractures; deformity cases)

Among identified patients (106), we:

- Manually screened operative notes
- Confirmed traumatic mechanism prior to inclusion
- Manual review allowed accurate isolation of true traumatic TL cohort

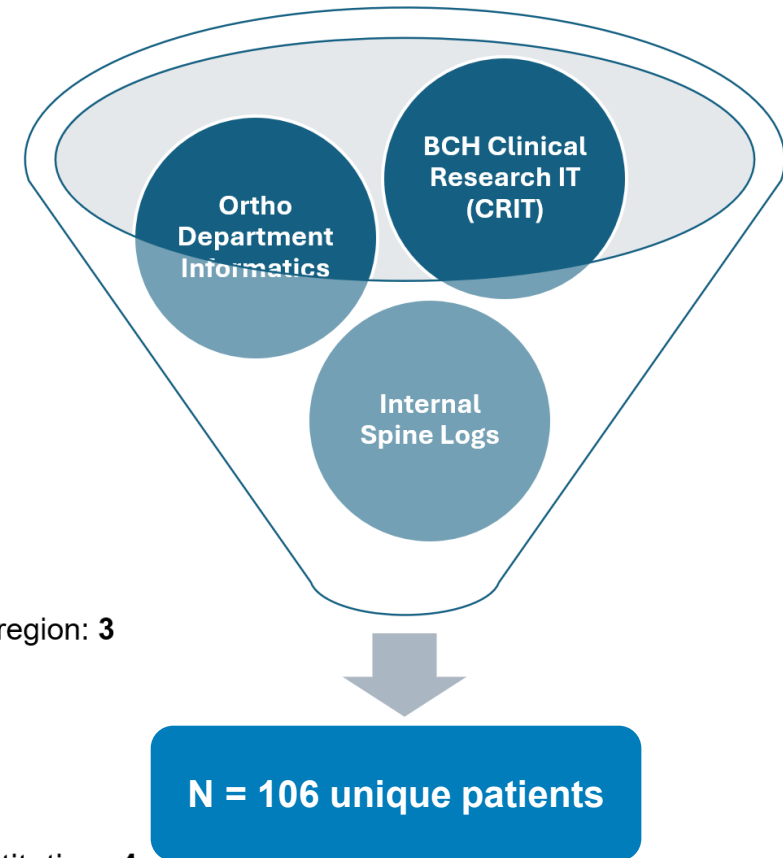
Screening Results at BCH

(*****Requires further verification*****)



- Pathologic Conditions: 17
- Scoliosis/Kyphosis: 14
- Congenital Complexities: 13
- Non-Traumatic Spondylolysis: 3
- Not Spine Related: 1
- Traumatic spine outside study defined TL region: 3

- Initially treated at non-CORTICES institution: 4
- Prior underlying spinal condition: 2



In REDCap:
 *Include all patients that meet inclusion criteria
 **Collect data on patients that meet *both* inclusion/exclusion criteria

REDCap Housekeeping: Record ID

- When entering your patient data, you will be asked to enter a new or existing **Record ID**.
- To generate your REDCap Record IDs, please use the following format (below), where '**S**' is the 2-digit site code and '**P**' is the 3-digit record ID

SS - PPP

2-digit Unique **Site** Number

3-digit Sequential **Patient** ID Number

For example, BCH's first patient would have a REDCap ID of "20-001". BCH's twentieth patient would have a REDCap ID of '20-020'. It is crucial that sites use the correct site ID to avoid duplicating REDCap IDs.

SITE #	SITE	SITE #	SITE
20	Boston Children's	30	Le Bonheur Children's
21	Carolinas Medical Center	31	Lurie Children's
22	Children's Atlanta	32	Nationwide Children's
23	Children's Colorado	33	Rady Children's
24	Children's Dallas	34	Seattle Children's
25	Children's LA USC	35	St. Louis Children's
26	Children's Philadelphia	36	Texas Children's
27	Cincinnati Children's	37	Vanderbilt Children's
28	CS Mott Children's (Michigan)	38	UCSF
29	Gillette Children's		

REDCap Housekeeping: Missing Data

- Utilize the missing code (i.e., no fields should be left blank) when appropriate. All fields are marked with a circular “M” indicate that a missing data code may be used

B6. Was the patient found to be neurologically deficit during the pre-operative work-up?

Look for note that mentions weakness, numbness, bladder or bowel function around time of injury.

Yes
 No

Mark field as:

[Clear value]

Missing or unavailable data (NA)

REDCap Housekeeping: Branching Logic

- Fields marked with a star icon (★) indicate branching questions that trigger follow-up or further nested sub-questions. To ensure completeness, review all starred fields and confirm any resulting sub-questions are fully answered.

★B7. Which of the following imaging modalities was utilized in documenting the confirmation of spinal fracture within the thoracolumbar region?

X-ray

MRI

CT

★B7a. If an MRI was performed, is there any skull/brain MRI imaging documented?

Yes

No

reset

★B7a1. If skull/brain MRI was performed, what were the findings?

Normal

Traumatic brain injury (TBI) / diffuse axonal injury

Intracranial hemorrhage (subdural, epidural, intraparenchymal)

Skull fracture

Other

Please look through radiologic notes and mark as indicated

B7a2. If skull/brain MRI demonstrated other findings not listed above, please specify:

Please keep your responses to 100 characters or less

Thoracolumbar Fractures CORTICES





PID 5732

Record Home Page

The grid below displays the form-by-form progress of data entered for the currently selected record. You may click on the colored status icons to access that form/event.

 Choose action for record ▾

Record ID **20-001**

 Data Collection Instrument	Status
Eligibility	
Data Form	
AO + TLICS	

REDCap Instruments

1) Eligibility Form

2) Data Collection Form

A. Demographics & Medical History


B. Injury Characteristic & Work-Up

C. Surgical Characteristics




D. Post-Operative Details & Complications

3) AO + TLICS SCORE



Eligibility Form



 Editing existing Record ID **20-053**.



Record ID 20-053
To rename the record, see the record action drop-down at top of the [Record Home Page](#).

Site:   Boston Children's 

Inclusion Criteria


Is the participant younger than 18 years at presentation? Yes No   reset
Patient considered to be no older than 18.99 at time of presentation


Has the patient undergone spinal surgery for thoracolumbar (TL) spinal trauma at CORTICES-specific institutions between January 2002 and June 2024? Yes No   reset
Thoracolumbar spinal trauma defined as spinal injury at any length along the thoracic to lumbar vertebral regions (T1-L5)


Was the patient's operative procedure treated by orthopedic surgeons, neurosurgeons, or a combination of both teams? Yes No   reset


Exclusion Criteria

Does the patient's spinal trauma fall into one of several categories that are NOT eligible for the study:

- Patient has non-fracture spinal injuries such as contusion or distortion ONLY**
- Patient has exclusive injuries to the spinal ligaments ONLY**
- Patient has vertebral fractures that extend to the cervical levels (i.e., outside of the thoracolumbar zone of interest) or isolated fractures exclusive to cervical or sacral levels**  Yes No reset
- Patient has isolated fractures exclusive to spinous, transverse processes, and the vertebral arch (i.e., non-load bearing elements of the spine).**



Did the patient have questionable fracture without clear radiologic evidence?  Yes No reset

Was the initial surgery for the thoracolumbar spine fracture performed at an EXTERNAL hospital NOT part of CORTICES?  Yes No reset

Does the patient have an underlying atraumatic spinal condition that required prior surgery?  Yes No reset
Example: Prior spinal fusion for non-traumatic condition (e.g., scoliosis) with subsequent traumatic injury requiring surgery.

Eligibility

If you answered **NO** for any of the **inclusion** questions or **YES** for any **exclusion** questions, the patient is **NOT** eligible for data collection. Please do not continue further.

Is the participant eligible for data collection  Yes No  reset

Data Extraction

Editing existing Record ID 20-053.

Record ID 20-053

A. Demographics & Medical History Demographics

A1. Demographics

A1. Patient's Date of Birth: 12-20-2008 Today M-D-Y

A2. Sex at Birth: Male Female

★A3. Race: White Black or African American Native American or Alaskan Native Asian Hispanic or Latino Hawaiian or Pacific Islander Other Refused

A4. Insurance: Uninsured Public Private

A2. Medical History

★A5. Is the patient noted to have any chronic illnesses? Yes No

★A5a. Chronic Conditions *Please mark all that apply.* Endocrine Gastrointestinal / Hepatic Immunologic Pulmonary Renal Other (specify)

★A6. Is the patient noted to have any developmental disabilities? Yes No

Department Specialty	Count	Last Date
<input checked="" type="checkbox"/> Allergy	23	06/04/2025
<input type="checkbox"/> Case Management	1	10/28/2024
<input type="checkbox"/> Child Life Services	1	10/22/2024
<input type="checkbox"/> Dermatology	37	07/16/2025
<input type="checkbox"/> Emergency Medicine	1	10/06/2024
<input type="checkbox"/> Financial Counseling and As...	1	11/04/2025
<input type="checkbox"/> General Surgery	1	10/07/2024
<input type="checkbox"/> Infectious Diseases	1	12/17/2025
<input type="checkbox"/> Internal Medicine	2	11/17/2024
<input type="checkbox"/> Medical Records	10	11/17/2024
<input type="checkbox"/> Oral Surgery	7	11/17/2024
<input type="checkbox"/> Orthopedic Surgery	4	11/17/2024
<input type="checkbox"/> Pediatric Dermatology	3	11/17/2024
<input type="checkbox"/> Pediatric Emergency Medicine	1	11/17/2024
<input type="checkbox"/> Pediatric Infectious Disease	6	11/17/2024
<input type="checkbox"/> Pediatric Neurosurgery	2	11/17/2024

Skin Exam
1. ATOPIC DERMATITIS, UNSPECIFIED TYPE
 Generalized
 Eczematous papules and plaques on the right forearm, right popliteal fossa, and right knee
 Within the central and lateral scars on his back are a few eczematous papules.
 ██████████ eczema is overall well controlled. He is not bothered by his current lesions.
 He does not need to restart dupilumab at this time. He declined any topical prescriptions. We discussed moisturizing with a cream if needed.

B. Injury Characteristics & Work-Up

B1. Injury Characteristic

B1. Date of **Injury**:

10-06-2024 Today M-D-Y

B1a. **Age** at time of **injury**:

15.8 View equation
[Autocalculated]

★B2. **Mechanism** of Injury:

- Motor vehicle collision (car, truck, van)
- Motorcycle / ATV accident
- Bicycle accident
- Fall from standing / ground level
- Fall from height
- Trampoline injury
- Sports-related injury
- Assault / non-accidental trauma
- Other

reset

B2a. If the spinal injury resulted from **motor vehicle accident**, was there any mention of the trauma being a **car seat related injury**?

- Yes
- No

reset

Please check the initial ED encounter or any subsequent clinical notes to see if a car seat was involved when the patient experienced trauma

★B2b. Please **specify the sport** that led to the spinal trauma:

- Baseball / Softball
- Football
- Gymnastics / Cheer
- Hockey
- Lacrosse
- Rugby
- Skating (ice/roller/inline)
- Skateboarding
- Skiing / Snowboarding
- Soccer
- Wrestling / Martial Arts
- Other sport (use free text to specify)

reset

B2. Clinical Work-Up

★B3. Which inpatient service was the patient first admitted to (following ED evaluation or outside transfer)?

- Orthopedics
- General Surgery
- Trauma Surgery
- Neurology
- Neurosurgery
- Other

reset

★B4. Which department services were formally consulted for this patient (documented consult note/order) between presentation and surgery?

- Orthopedics
- Neurology
- Neurosurgery
- Emergency Department
- General Surgery
- Trauma Surgery
- Cardiology
- Radiology
- Anesthesiology
- Gastroenterology
- Pulmonology
- Intensive Care Team
- Physiatry Medicine & Rehabilitation (PM&R)
- Other

Count only services that were formally consulted with a documented consult order and/or consult note in the EMR. Do not include services that only evaluated the patient in the ED as part of routine care.

B4a. If additional departments were involved in assessing the patient, please specify:

Ophthalmology; Urology; Plastic/Oral Surgery
Use the free text option to specify "other" department(s). Please try to keep your response to 100 characters or less.

B5. During the clinical workup, which of the following vertebral levels were found to be fractured?

- T1
- T2
- T3
- T4
- T5
- T6
- T7
- T8
- T9
- T10
- T11
- T12
- L1
- L2
- L3
- L4
- L5

NOTE: Most thoracolumbar injuries involve one to two vertebral body fractures. If three or more vertebral bodies are documented, please confirm accuracy or confirm with PI.

Discharge and Progress Report summarizes course of stay & answers most of these questions related to clinical workup

History of Present Illness

Hospital Course

HPI:

presenting with PMH of atopic dermatitis who presents as a transfer from OSH after MVC. He was reportedly the passenger, ejected, and hit a tree head on. Reportedly confused but semi-alert on scene. On presentation to OSH, he was hypotensive and complaining of diffuse abdominal pain. He was taken directly to the operating room where he underwent exploratory laparotomy, splenectomy, bladder rupture repair, and a sigmoid colon injury was over sewn. He received at least 8U pRBC, 4U FFP, 1U platelets, 1U cryo, 1g TXA, and 2g calcium before arrival here. He was transported sedated on propofol gtt with fentanyl boluses.

(B3)

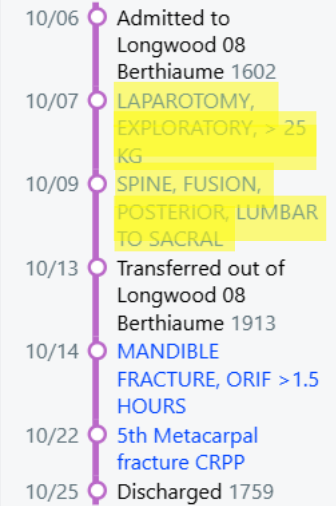
After arrival to MSICU found to have multiple additional traumatic injuries including multiple facial fractures including bilateral Lefort 2 fractures, L open globe injury, R calcaneus fracture, L5 vertebral body fx, and S2-S5 fractures with spinal canal stenosis

Neuro: kept intubated and sedated on infusions through 10/11. A c collar was kept in place and full spine precautions were maintained. He went to the OR w/ NSGY and ortho for a spinal fusion procedure and repair of dura on 10/9 which was uncomplicated. Started on a morphine PCA on 10/10.

(B4)

Ophtho: He underwent repair of L ocular laceration w/ uveal prolapse and removal of glass foreign bodies from bilateral conjunctiva on 10/7. He was kept on IV antibiotics for 48 hours to prevent infection in setting of open globe injury. He was started on topical drops and ointments on POD1 w/ eye shield remaining in place otherwise.

Care Timeline



GU: Urology was consulted for history of bladder rupture s/p repair at OSH. His foley was maintained for 10 days per their recommendations. His hematuria slowly improved.



Clinical Workup: Advanced Imaging

★B7. Which of the following imaging modalities was utilized in documenting the confirmation of spinal fracture within the thoracolumbar region?

X-ray
 MRI
 CT

★B7c. If a CT scan was performed, is there any skull/brain CT imaging documented?

Yes
 No

★B7a. If an MRI was performed, is there any skull/brain MRI imaging documented?

Yes
 No

★B7c1. If skull/brain CT scan was performed, what were the findings?

Normal
 Skull fracture
 Intracranial hemorrhage (epidural, subdural, SAH, intraparenchymal)
 Cerebral edema
 Midline shift/herniation
 Other

Please look through radiologic notes and mark as indicated

B7a1. If skull/brain MRI was performed, what were the findings?

Normal
 Traumatic brain injury (TBI) / diffuse axonal injury
 Intracranial hemorrhage (subdural, epidural, intraparenchymal)
 Skull fracture
 Other

Please look through radiologic notes and mark as indicated

B7a2. If skull/brain MRI demonstrated other findings not listed above, please specify:

Please keep your responses to 100 characters or less

★B7b. If an MRI was performed, is there any spine MRI imaging documented?

Yes
 No

★B7d. If a CT scan was performed, is there any spine CT imaging documented?

Yes
 No

★B7b1. If spine MRI was performed, what were the findings?

Normal (only fracture was noted)
 Spinal cord injury with contusion
 Cord transection
 Epidural hematoma
 Spinal stenosis
 Posterior ligamentous complex (PLC) disruption
 Disc herniation
 Other

Please look through radiologic notes and mark as indicated

★B7d1. If spine CT scan was performed, what were the findings?

Normal (only fracture was noted)
 Retropulsion / canal compromise
 Pedicle/lamina fracture
 Other associated injuries (rib fracture, posterior element injury, etc.)
 Other

Please look through radiologic notes and mark as indicated

B7b2. If spine MRI demonstrated other findings not listed above, please specify:

Please keep your responses to 100 characters or less

B7d2. If spine CT scan demonstrated other findings not listed above, please specify:

Please keep your responses to 100 characters or less

Date Presentation: 10/06/2024

Injured Levels:

Closed Burst fracture of L5

Displaced zone I fracture of sacrum

Operative Date: 10/09/2024

Imaging:

Study Date Time	Proc Description	Image Co...	Modal
mm/dd/yyyy			
10/06/2024 4:24:27 PM	XR CHEST SERIAL 2	2	DX
10/06/2024 6:04:22 PM	CT HEAD WO IV CONTRAST	3776	CT
10/06/2024 6:04:22 PM	CT CERVICAL SPINE WO IV CONTRAST	2147	CT
10/06/2024 6:04:22 PM	CT CHEST ABDOMEN PELVIS W CONTRAST	4253	CT
10/06/2024 6:24:16 PM	CT MAXILLOFACIAL WO IV CONTRAST	0	CT
10/06/2024 7:01:20 PM	CT PELVIS WO IV CONTRAST	3296	CT

10/12/2024 5:13:08 PM	MR CERVICAL SPINE WO CONTRAST	234	MR
10/12/2024 5:58:22 PM	MR KNEE RIGHT WO CONTRAST	594	MR
10/14/2024 6:09:04 PM	XR CHEST 1 VIEW	1	DX
10/15/2024 1:01:18 PM	CT FOOT RIGHT WO IV CONTRAST	1431	CT

*MRI from 10/12/2024 irrelevant to levels operatively managed

C. Surgical Characteristics

C1. Operative Details

C1. Date admitted to CORITCES institution: 10-06-2024 Today M-D-Y

C1a. Date of surgery: 10-09-2024 Today M-D-Y

C1b. Age at time of surgery: 15.8 View equation [Autocalculated]

C1c. Time between admit date and surgery (in days): 3 View equation [Autocalculated]

★C2. Was there any pre-op lab work conducted? Yes No reset

C2a. Hemoglobin (g/dL) 14.6

C2b. White Blood Cells (x 1000/ μ L) 14.40

C2c. Neutrophils (%) 76.90

C3. What medical team was involved during the course of the surgery?
 Orthopedic Surgery Only
 Neurosurgery Only
 Combined Orthopedic + Neurosurgery Team reset

C3a. Please indicate which provider(s) were present from each service during the index surgery:

	Orthopaedics	Neurosurgery
Primary Attending	<input checked="" type="checkbox"/>	<input checked="" type="checkbox"/>
2nd Attending	<input type="checkbox"/>	<input type="checkbox"/>
Fellow	<input checked="" type="checkbox"/>	<input type="checkbox"/>
Resident	<input type="checkbox"/>	<input checked="" type="checkbox"/>
PA/NP	<input type="checkbox"/>	<input type="checkbox"/>

C4. Did the patient undergo an open or minimally invasive surgery? Open Minimally Invasive Surgery reset

Encounters Notes Labs Imaging Cardiology Procedures Meds LDAs Media Letters Episodes Referrals Other Orders SnapShot Neurology

Preview Refresh Pt Msg Review Route Edit Note

Filters Hide Add'l Notes Me LWIPTH H/P DC Sum Consults Op Notes Prescriber Only

10/09/2024 15:14	Op Note	Admission (Dis... See, Pokmeng, MD - Physician - Neurosurgery	Neurosurgery
10/09/2024 15:14	Brief Op Note	Admission (Dis... Yearley, Alexander, MD - Resident - Neurosurgery	Neurosurgery
10/09/2024 15:14	Brief Op Note	Admission (Dis... Liu, David S, MD - Fellow - Orthopedics	Orthopedics
10/09/2024 15:14	Op Note	Admission (Dis... Birch, Craig, MD - Physician - Orthopedics	Orthopedics

Case Time:
10/9/2024 3:14 PM

Procedures:
SPINE, FUSION, POSTERIOR,
LUMBAR TO SACRAL
LAMINECTOMY,
DECOMPRESSION/EXPLORATION

Surgeons:
Craig Birch, MD
Pokmeng See, MD
Alexander Yearley, MD
David S Liu, MD



Tip: All operative questions (C4—C12) should be found in operative notes from the ortho and/or neurosurgery attending

C4. Did the patient undergo an **open or minimally invasive surgery?** Open Minimally Invasive Surgery reset

★C5. Did the patient undergo a **fusion and/or instrumentation procedure?** Yes No reset

Please look through operative notes and mark as indicated

★C5a. What form of **fusion/instrumentation procedure did the patient undergo?** Posterior Spinal Fusion (PSF) Combined Anterior + Posterior Spinal Fusion Anterior Spinal Fusion (ASF) Instrumentation without Fusion reset

C5a1. If a **Posterior Spinal Fusion was performed, please specify the technique:** No Interbody Fusion [posterior/posterolateral fusion only without interbody fusion] Posterior Lumbar Interbody Fusion (PLIF) Transforaminal Lumbar Interbody Fusion (TLIF)

C5b. What levels were **fused in the spinal fusion?** T1 T2 T3 T4 T5 T6 T7 T8 T9 T10 T11 T12 L1 L2 L3 L4 L5 Sacrum Pelvis

★C5c. Was there **bone graft used during the course of the procedure?** Bone graft not utilized Autograft Allograft Synthetic bone graft Other reset

Please mark all that apply:

C5d. What levels were **instrumented?** T1 T2 T3 T4 T5 T6 T7 T8 T9 T10 T11 T12 L1 L2 L3 L4 L5 Sacrum Pelvis

★C5e. What type of **instrumentation(s) was utilized during the procedure?** reset

Please mark all that apply:

No instrumentations done at any vertebral level Screws Hooks Cage Other

Ortho Attending Operative and Post-op Notes

Procedures:

1. Posterior spinal fusion of L5 to the pelvis using S2AI screws
2. Posterior spinal instrumentation from L4-pelvis using S2AI screws
3. Open treatment of pelvic ring fracture
4. Use of computer assisted navigation
5. Autograft for spine surgery.
6. Allograft for spine surgery (30 cc cancellous allograft)

Modifier:

22 modifier was applied to this case given the severely comminuted nature of the fracture in polytrauma patient. Patient sustained an open pelvic fracture into the bladder with associated spinopelvic dissociation injury with L5 vertebral body fracture, severely comminuted sacral fracture with associated dural injury. Non orthopedic injuries included bowel injury, bladder injury, intra-abdominal hemorrhage requiring splenectomy, midface fractures, left orbital injury and left eye injury.

15 y.o. male polytrauma with **U-type sacral fracture, L5 vertebral body fracture**
 now s/p L5-pelvis PSF with instrumentation L4-S2AI, L5-S2 decompression, traumatic dural tear repair x2 (Birch/See, 10/9)
 Other orthopedic injuries:
 R comminuted minimally displaced calcaneus fracture
 R cuboid avulsion fracture
 B superior/inferior pubic rami fractures
 R knee tibia spine avulsion fx

Tip: All operative questions (C4—C12) should be found in operative notes from the ortho and/or neurosurgery attending

★C6. Did the patient undergo some form of **decompression** procedure? H M Yes No reset
Please look through operative notes and mark as indicated

★C6a. Which **decompression procedures** were performed during surgery? H M Laminectomy Corpectomy Discectomy Other

C6a1. If another decompression technique not listed above was performed, **please specify:** H M laminotomy and foraminal decompression
Please keep your responses to 100 characters or less

C6b. What levels were involved in the **decompression?** H M T1 T2 T3 T4 T5 T6 T7 T8 T9 T10 T11 T12 L1 L2 L3 L4 L5 Sacrum

Tip: Decompression procedures usually described by neurosurgeon if there is a joint Orthopaedic and Neurosurgery procedure:

They turned the surgical field over to us and we performed right side sacral laminectomy and partial left S2 laminotomy. There was evidence of dural disruption in multiple locations. I was able to primarily repair 1 large dural tear, but another complex dural tear was not amenable to suture repair and I maintained the lamina dorsal to this to provide local compression via Tisseel and Gelfoam. Between the S1 and S2 nerve root on the right, were able to palpate the displaced sacral body. Despite distraction on the rods bilaterally, were unable to depress this ventrally. However, inspection and the S1 and S2 foraminal space demonstrated no compression and no stenosis. The central canal is also widely decompressed. With slight reduction of the left-sided distraction, there was complete return of the left gastrocnemius motor evoked potential signals. Again, there was preservation of the improvement in the sphincter EMG signal bilaterally more dramatic on the right than the left. In the context of overall favorable neuromonitoring changes with no worsening of any signal, we decided to conclude the decompression and instrumentation to avoid further dural or nerve root injury. We obtained a final O-arm spin demonstrating wide decompression and based on this palpated the right S3 nerve root foramen and performed 2 additional bites of Kerrison rongeur to ensure adequate right S2 foraminal decompression.

Tip: All operative questions (C4—C12) should be found in operative notes from the ortho and/or neurosurgery attending

★C7. Was **navigation** utilized during the course of the procedure?

Yes
 No

★C7a. If **navigation** was used, please check all that apply:

CT based navigation
 Robotic navigation
 Other

C8. What type(s) of **intraoperative imaging** was used during the procedure?

No intraoperative imaging
 C-arm fluoroscopy (2D)
 O-arm CT spin (CT)
 Spine ultrasound

C9. Estimated **Blood Loss** (in mL):

200
Please make sure EBL is noted in mL

★C10. Was there an **intra-operative transfusion** conducted?

Yes
 No

★C11. Was there **indication of a dural injury** sustained?

Yes
 No

C11a. What was the **suspected cause for the damage** to the spinal dura?

Traumatic (present before surgery)
 Iatrogenic (caused during surgery)

★C11b. If the spinal dura had indications of injury, was the **dural injury repaired**?

Yes
 No

★C11b1. If the **dura was repaired**, how was it **operatively managed**?

Direct repair (primary suture repair)
 Augmented repair with patch
 Lumbar drain
 Other

★C12. Was there **intraoperative neuromonitoring** available during the procedure?

Yes
 No

C12a. If **neuromonitoring** was used, what **type of neuromonitoring** was utilized?

Motor Evoked Potential neuromonitoring (MEPs)
 Somatosensory Evoked Potentials (SSEPs)
 Both MEPs [Option 1] and SSEPs [Option 2]

Please note that MEPs and SSEPs can be used in conjunction. If this is the case, please select option 3 from the available radio options

C12b. Based on the neuromonitoring reading, was there any **indication of an intraoperative change**?

No change
 Worsening
 Improvement without complete resolution
 Complete resolution

- Procedures:**
1. Posterior spinal fusion of L5 to the pelvis using S2AI screws
 2. Posterior spinal instrumentation from L4-pelvis using S2AI screws
 3. Open treatment of pelvic ring fracture
 4. Use of computer assisted navigation
 5. Autograft for spine surgery.
 6. Allograft for spine surgery (30 cc cancellous allograft)

Proc Description	Accession No	Image Co...	Modality
10/09/2024 5:57:19 PM FL CARM FLUOROSCOPY 1 HOUR OR LESS	101012804	10	RF
10/09/2024 3:52:23 PM FL OARM 1 HOUR OR LESS	101012809	2437	CT

C-Arm / O-Arm
(Logged in PACS)

They turned the surgical field over to us and we performed right side sacral laminectomy and partial left S2 laminotomy. There was **evidence of dural disruption** in multiple locations. I was able to primarily **repair 1 large dural tear**, but another complex dural tear was not amenable to suture repair and I maintained the lamina dorsal to this to provide local compression via **Tisseel and Gelfoam**.

Neurosurgery Attending Operative Note

Nerve monitoring, including **SSEPs and transcranial MEPs**, were set up.

The feet did not have reliable signals at the start of the case. Similar with the anal sphincter signals. After decompression and reduction with stabilization, these signals improved from baseline. At the end of the case, **all signals were present and monitorable**.

Ortho Attending Operative Note

D. Post-Operative Details & Complications

D1. Post-OP ICU & Discharge

★D1. Was patient required to stay in ICU as part of post-operative care? Yes No reset

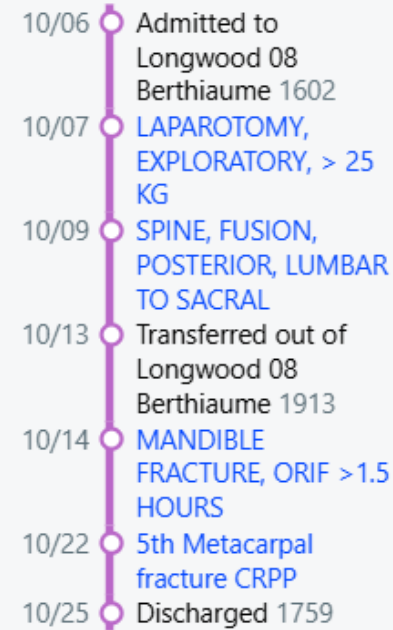
D1a. When was the patient admitted to the ICU? M-D-Y H:M

D1b. When was the patient discharged from the ICU? M-D-Y H:M

D2. Date when patient was discharged: M-D-Y
If the patient died during the index hospitalization, record the date of death as the discharge date.

D3. Where was the patient discharged to? Home Rehab facility Patient passed away (polytrauma, complications, etc.) reset

Care Timeline



Discharge

Other Acute Hospital

AVS - Discharge to Home (English View) (Snapshot) - Printed 10/25/2024

Follow-Ups: Follow up with Nathan Faulkner, MD (Pediatrics)

Date of Service: 10/13/2024 7:31 PM

Signed

NURSING TRANSFER NOTE

Patient Location: LW 08 BERTHIAUME

I - Illness Severity

CHEWS Score: /

Acute Care CAMEO: /

P - Patient Summary

Events of the day: Arrived to 10 mandel at ~ 1850. Afebrile, VSS. Pain controlled with PCA morphine. Swelling and edema to face. Bilateral red scleras, L eye surgical site edematous, eye shield present. Swelling to mouth and lips noted. C collar in place. Abd midline incision with steri strips CDI. R foot in boot. Foley intact. Sinus precautions maintained. Lipids infusing via PIV. NPO at midnight - OR w/ plastics 10/14. Mother and father at bedside.

Tip: Check Transfer and Progress Notes In this case: Pt transfer ICU → Floor

D2. Complications, Additional Surgeries, & Hospitalizations

★D4. Following the index surgery, did the patient require any of the following **unplanned healthcare services NOT involving a return** to the operating room?

PLEASE ENSURE THAT YOU ARE ANSWERING THESE QUESTIONS ONLY IN RELATION TO THE SPINE TRAUMA (i.e., ONLY HOSPITAL ENCOUNTERS THAT RELATE TO THE THORACOLUMBAR FRACTURES)

Please mark all that apply:

- No, none of the below
- Post-index surgery emergency department visit(s)
- Post-index surgery unexpected hospitalization(s)
- Post-index surgery ICU stay(s)

★D4a. How many times did the patient come to the ED post-index surgery?

1

Please note that the ED visit MUST BE in relation to the spinal trauma

D4a1. Date of post-index surgery ED visit (#1):

Today M-D-Y

★D4b. How many times did the patient have an unexpected hospitalization?

1

Please note that the unexpected hospitalization visit MUST BE in relation to the spinal trauma

D4b1. Date of post-index surgery unexpected hospitalization (#1):

Today M-D-Y

★D4c. How many times did the patient have a post-index surgery ICU stay?

1

Please note that the post-index surgery ICU stay visit MUST BE in relation to the spinal trauma

D4c1. Date of post-index surgery ICU stay (#1):

Today M-D-Y

★D5. Did the patient experience any complications requiring additional surgery following the index procedure?

Yes

No

reset

D5a. If additional procedures were required, how many post-index procedures were performed on the patient?

1

D5.1a. Date of re-operation (#1):

Today M-D-Y

★D5.1b. What was the primary indication for the reoperation (#1)?

Implant failure/revision

★D5.1c. What was the type of reoperative (#1) procedure that was performed?

- Irrigation & Debridement (I&D for infection)
- Hardware removal
- Revision fusion
- Other

Please mark all that apply:

D5.1d. What was the estimated blood loss (EBL) in this reoperative (#1) procedure (in mL)?

Please make sure EBL is noted in mL

D5.1e. Date when patient was discharged after re-operation (#1):

Today M-D-Y

D6. What is the last date of follow-up on file for this patient?

Today M-D-Y

Form D2 – Re-Hospitalizations & Re-Operations

D4) Re-Hospitalizations (Post-Discharge)

- Follow-up ED visit
- Unexpected inpatient hospitalization
- ICU readmission

Enter dates only (up to 5 dates per category)

D5) Re-Operations

- Number of re-operations (up to 5)
- Dates of re-operation
- Primary indication
 - Infection
 - Implant failure/revision
 - Planned vs. Unplanned

★D5.1b. What was the primary indication for the reoperation (#1)?

Implant failure/revision

D5.1b1. Was this implant revision planned (i.e., a staged procedure or part of the pre-planned surgical approach)?

- No - Unplanned/unexpected implant revision
- Yes - Planned/staged procedure

reset

- Neurologic deterioration
- Wound complication
- Additional procedures performed
 - I&D for infection
 - Hardware removal
 - Revision fusion
- Estimated Blood Loss
- Date discharged after re-operation

D6) Last date of follow-up

AO TL Classification TLICS

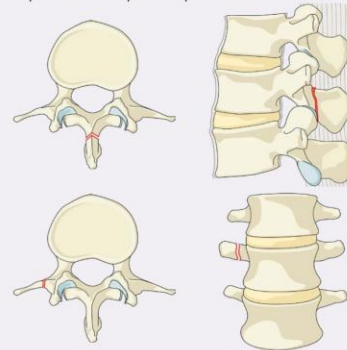
Spine Trauma Case Examples

Craig M Birch, MD

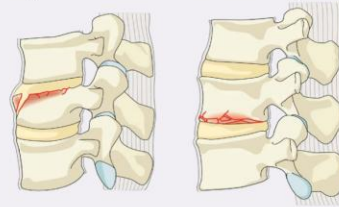
AO Classification:

Type A Compression Injuries

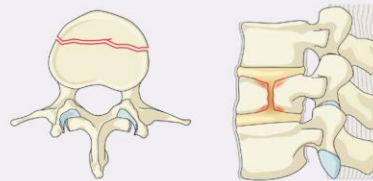
A0 Minor, nonstructural fractures
Fractures, which do not compromise the structural integrity of the spinal column such as transverse process or spinous process fractures.



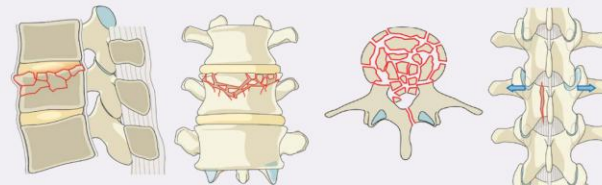
A1 Wedge-compression
Fracture of a single endplate without involvement of the posterior wall of the vertebral body.



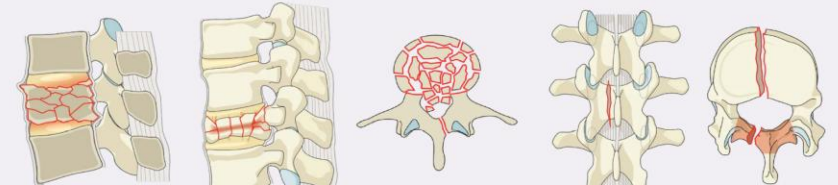
A2 Split
Fracture of both endplates without involvement of the posterior wall of the vertebral body.



A3 Incomplete burst
Fracture with any involvement of the posterior wall; only a single endplate fractured. Vertical fracture of the lamina is usually present and does not constitute a tension band failure.

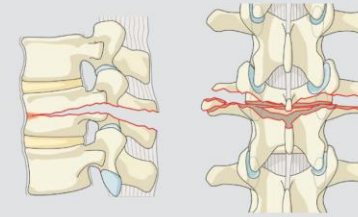


A4 Complete burst
Fracture with any involvement of the posterior wall and both endplates. Vertical fracture of the lamina is usually present and does not constitute a tension band failure.

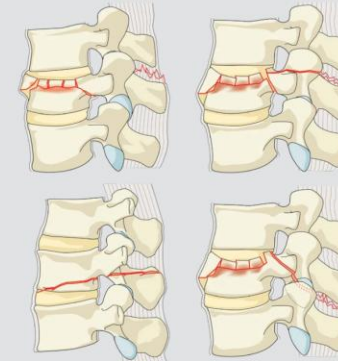


Type B Distraction Injuries

B1 Transosseous tension band disruption Chance fracture
Monosegmental pure osseous failure of the posterior tension band. The classical Chance fracture.

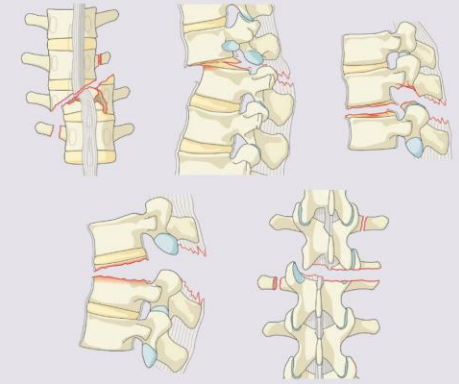


B2 Posterior tension band disruption
Bony and/or ligamentary failure of the posterior tension band together with a Type A fracture. Type A fracture should be classified separately.

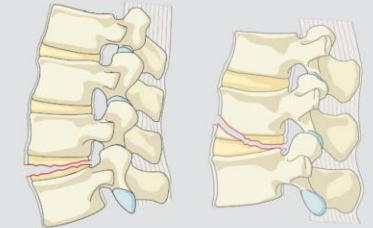


Type C Translation Injuries

C Displacement or dislocation
There are no subtypes because various configurations are possible due to dissociation/dislocation. Can be combined with subtypes of A or B.

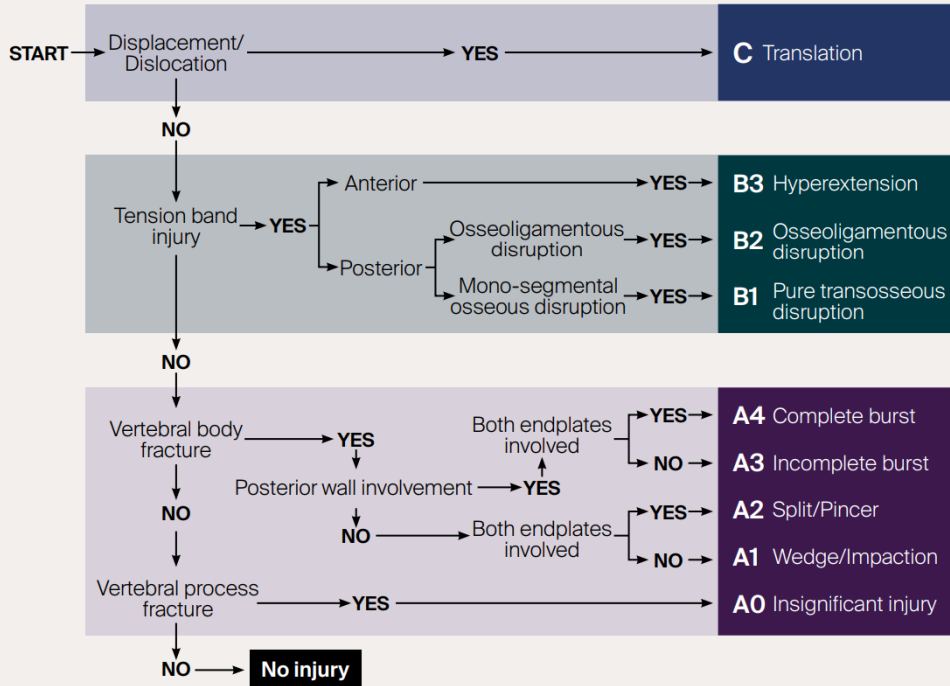


B3 Hyperextension
Injury through the disk or vertebral body leading to a hyperextended position of the spinal column. Commonly seen in ankylotic disorders. Anterior structures, especially the ALL are ruptured but there is a posterior hinge preventing further displacement.



AO Classification Algorithm:

Algorithm for morphologic classification



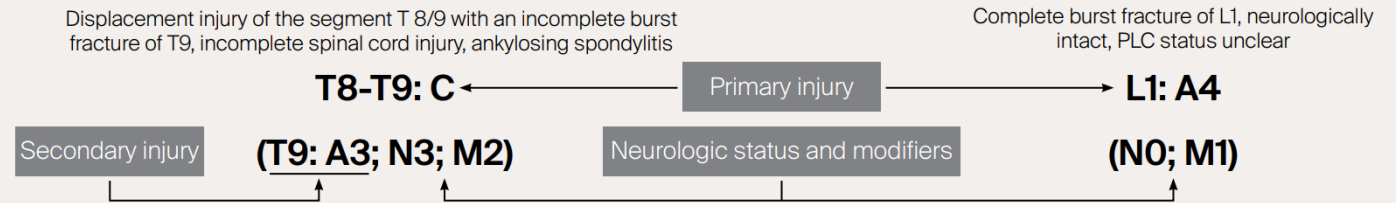
Neurology

Type	Neurological
N0	Neurology intact
N1	Transient neurologic deficit
N2	Radicular symptoms
N3	Incomplete spinal cord injury or any degree of cauda equina injury
N4	Complete spinal cord injury
NX	Cannot be examined
+	Continued spinal cord compression

Modifiers

Type	Description
M1	This modifier is used to designate fractures with an indeterminate injury to the tension band based on spinal imaging with or without MRI. This modifier is important for designating those injuries with stable injuries from a bony standpoint for which ligamentous insufficiency may help determine whether operative stabilization is a consideration.
M2	Is used to designate a patient-specific comorbidity, which might argue either for or against surgery for patients with relative surgical indications. Examples of an M2 modifier include ankylosing spondylitis or burns affecting the skin overlying the injured spine.

Classification Nomenclature

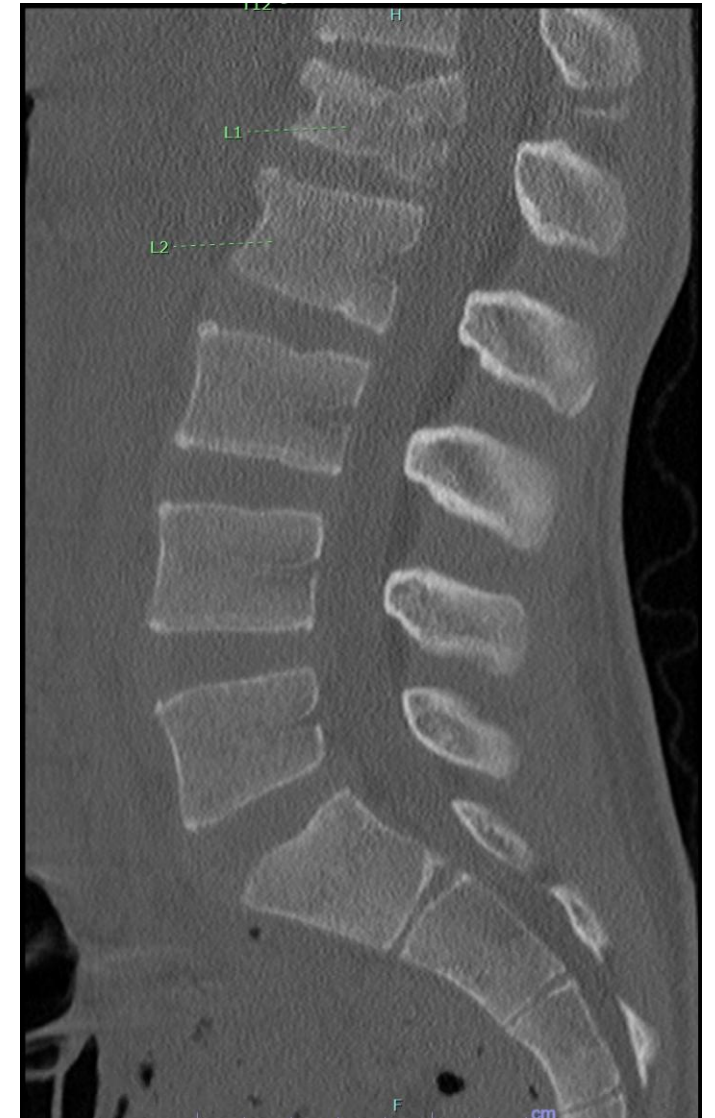

TLICS:

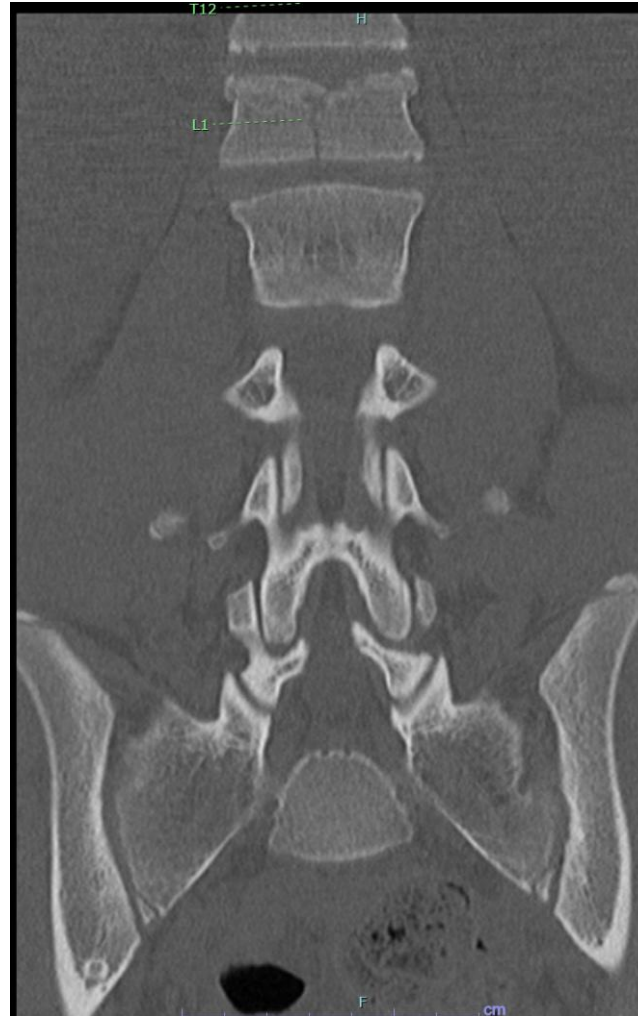TLICS 3 independent predictors				
1	Morphology immediate stability	<ul style="list-style-type: none"> - Compression - Burst - Translation/rotation - Distraction 	1 2 3 4	<ul style="list-style-type: none"> - Radiographs - CT
2	Integrity of PLC longterm stability	<ul style="list-style-type: none"> - Intact - Suspected - Injured 	0 2 3	<ul style="list-style-type: none"> - MRI
3	Neurological status	<ul style="list-style-type: none"> - Intact - Nerve root - Complete cord - Incomplete cord - Cauda equina 	0 2 2 3 3	<ul style="list-style-type: none"> - Physical examination
Predicts		<ul style="list-style-type: none"> - Need for surgery 	0 – 3 4 > 4	<ul style="list-style-type: none"> - nonsurgical - surgeon's choice - surgical

Case 1:

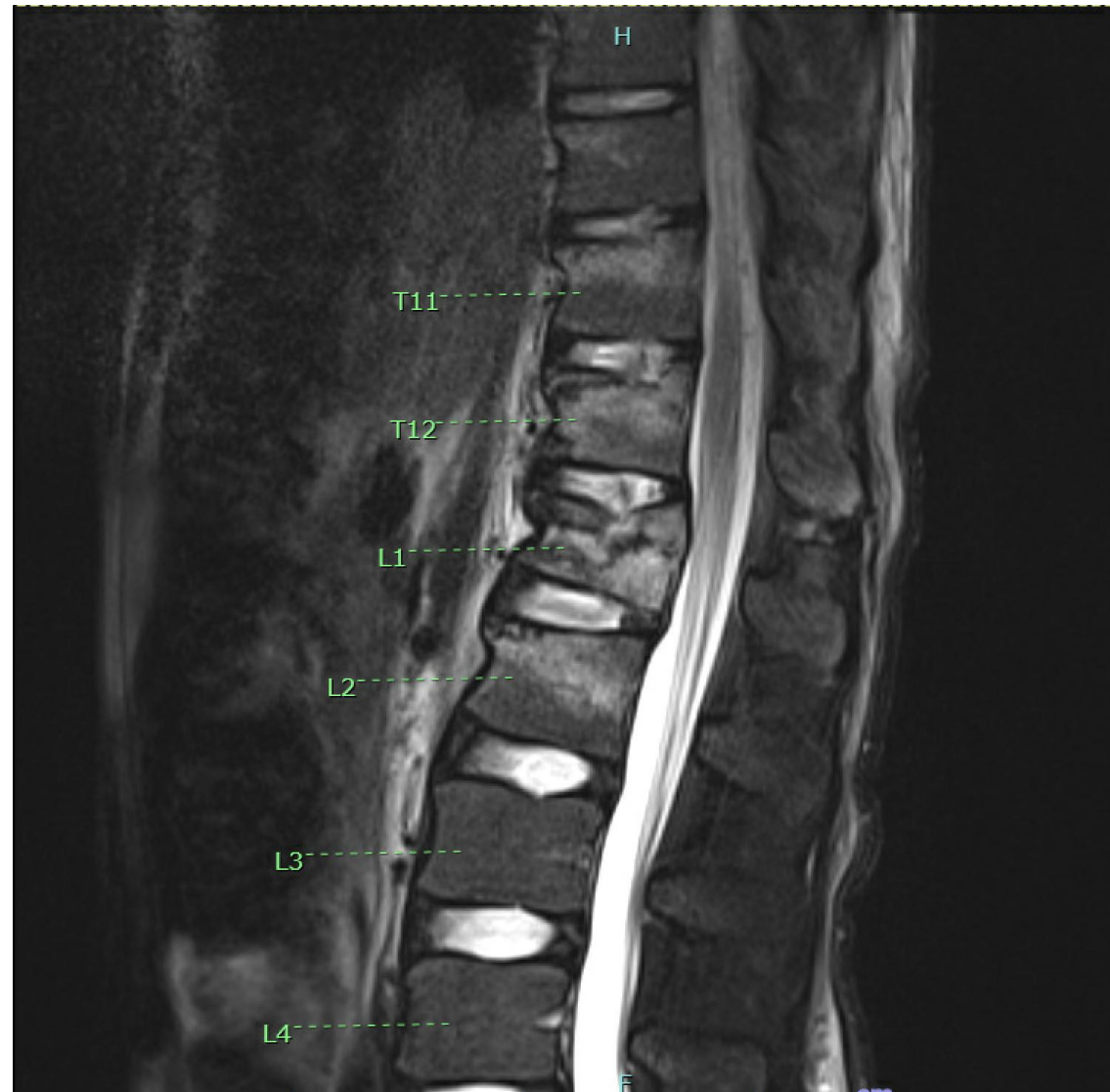
- 15 year old male
- Otherwise healthy
- Crashed BMX bike while going off a jump



Case 1:

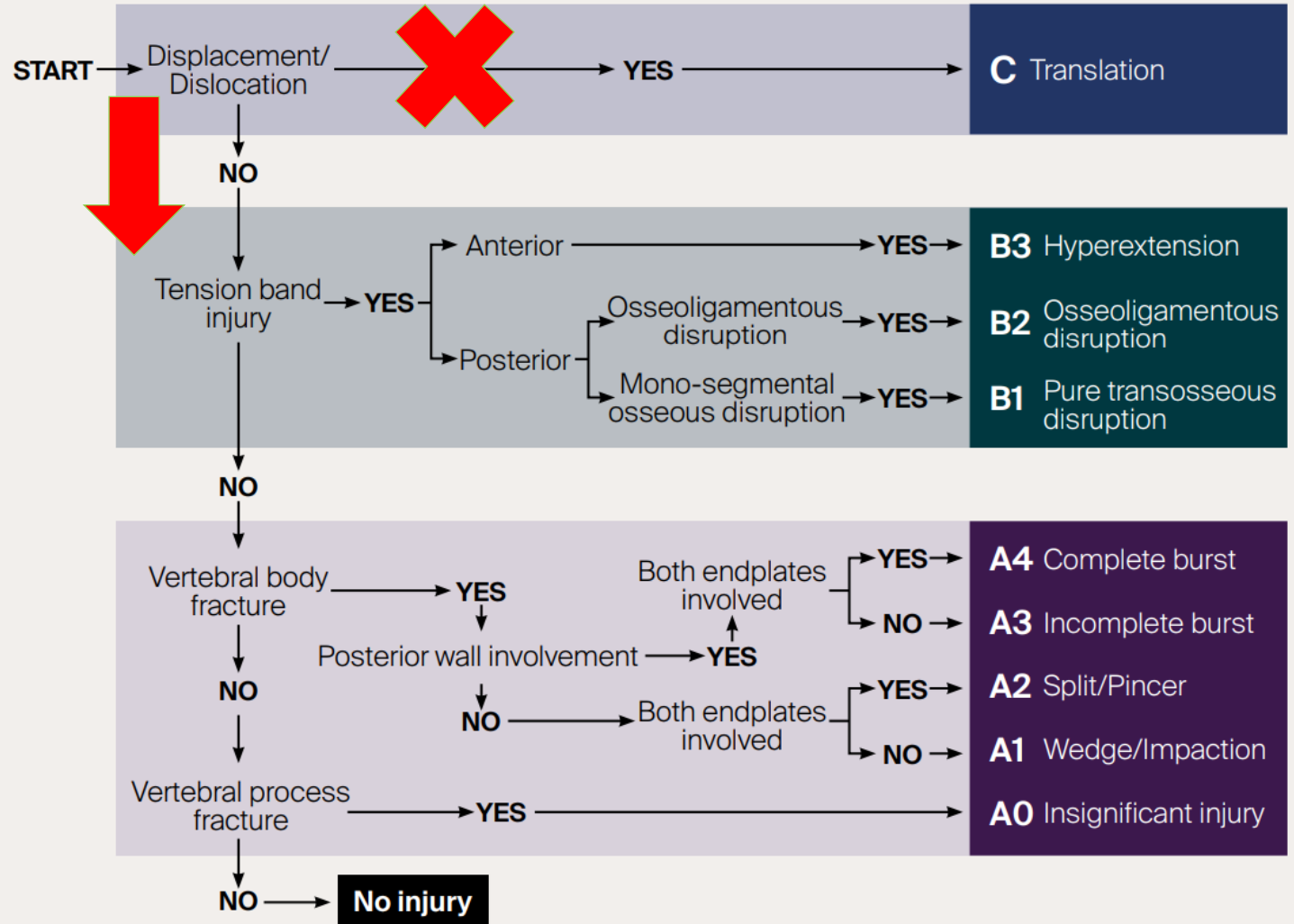


Case 1:



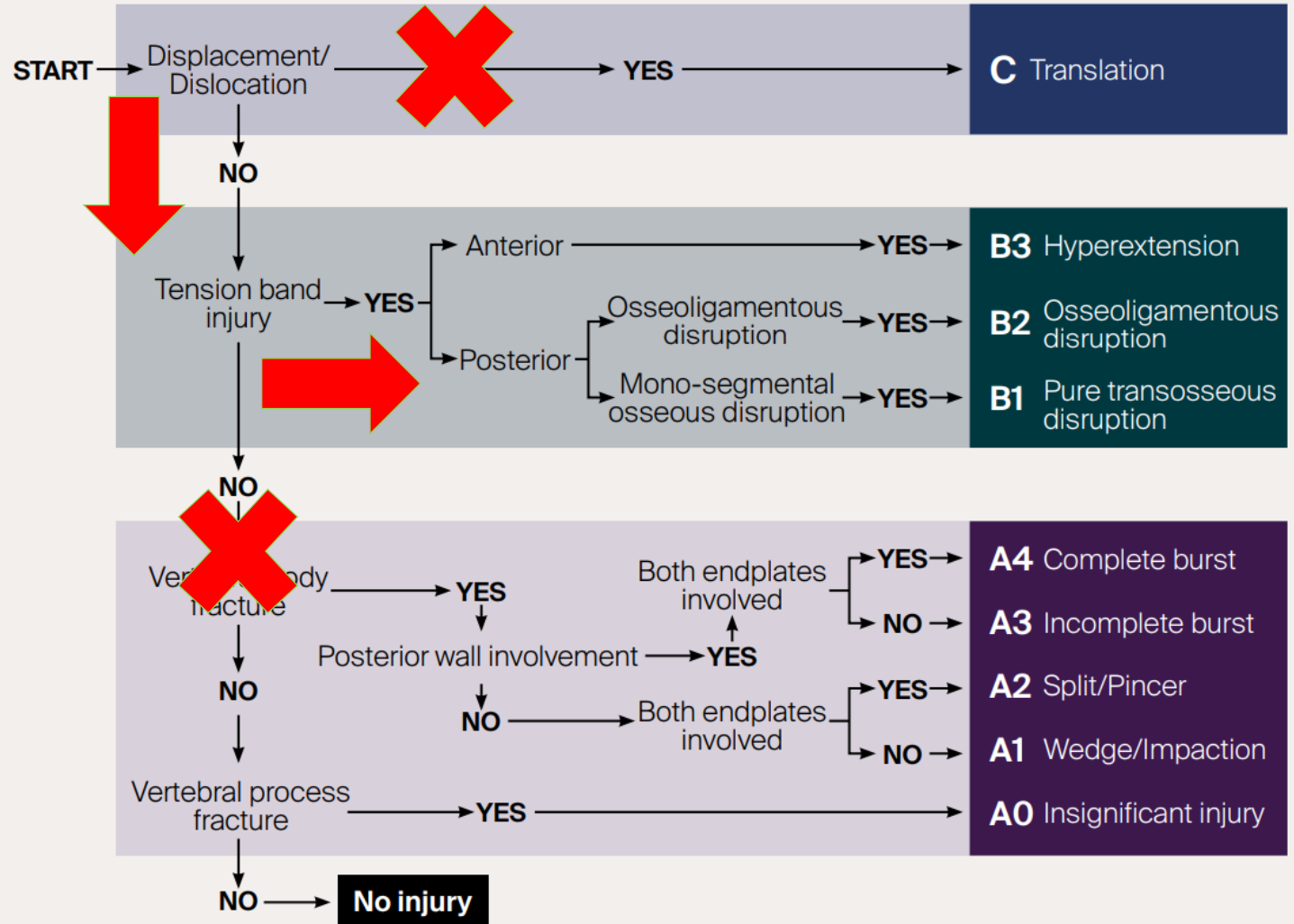
Case 1:

Algorithm for morphologic classification



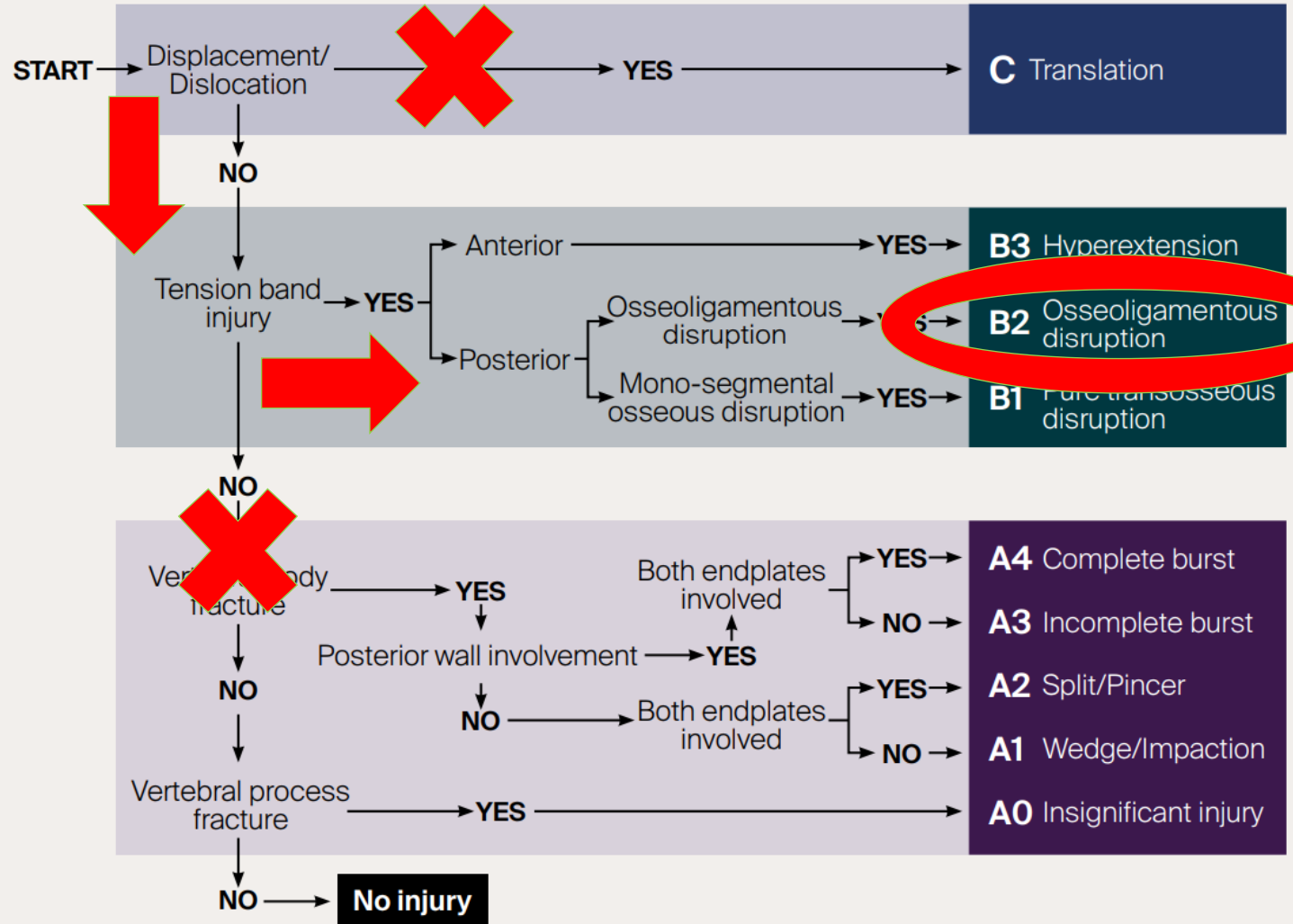
Case 1:

Algorithm for morphologic classification



Case 1:

Algorithm for morphologic classification

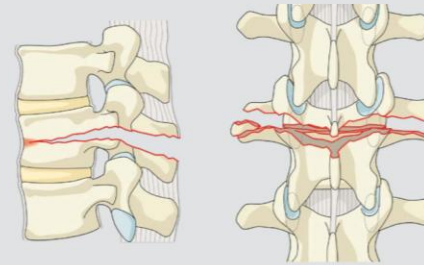


Case 1:

Type B Distraction Injuries

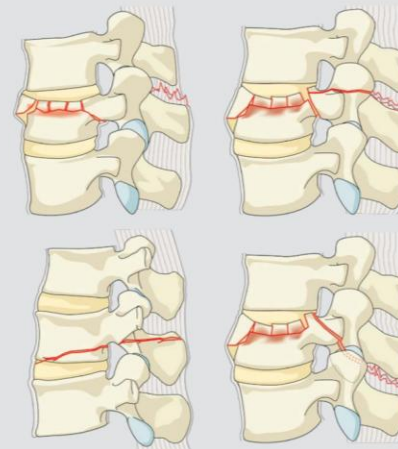
B1 Transosseous tension band disruption Chance fracture

Monosegmental pure osseous failure of the posterior tension band. The classical Chance fracture.



B2 Posterior tension band disruption

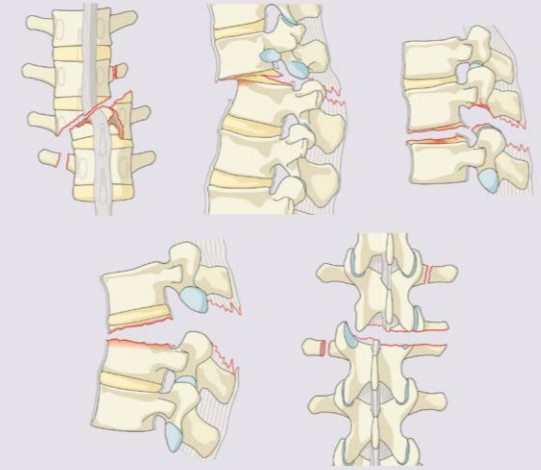
Bony and/or ligamentary failure of the posterior tension band together with a Type A fracture. Type A fracture should be classified separately.



Type C Translation Injuries

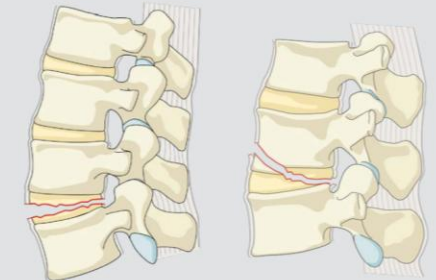
C Displacement or dislocation

There are no subtypes because various configurations are possible due to dissociation/dislocation. Can be combined with subtypes of A or B.



B3 Hyperextension

Injury through the disk or vertebral body leading to a hyperextended position of the spinal column. Commonly seen in ankylotic disorders. Anterior structures, especially the ALL are ruptured but there is a posterior hinge preventing further displacement.



Case 1:

Neurology

Type	Neurological
N0	Neurology intact
N1	Transient neurologic deficit
N2	Radicular symptoms
N3	Incomplete spinal cord injury or any degree of cauda equina injury
N4	Complete spinal cord injury
NX	Cannot be examined
+	Continued spinal cord compression

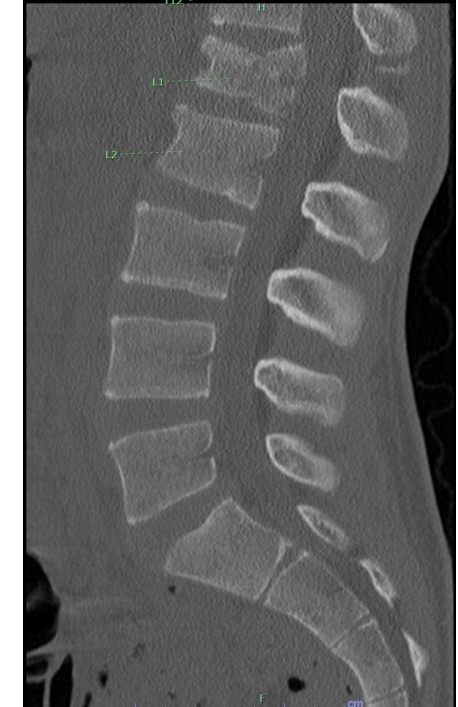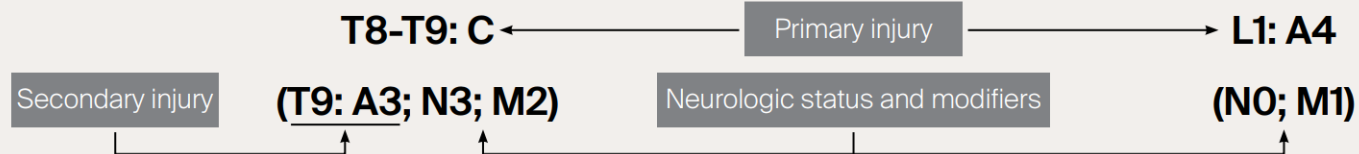
Modifiers

Type	Description
M1	This modifier is used to designate fractures with an indeterminate injury to the tension band based on spinal imaging with or without MRI. This modifier is important for designating those injuries with stable injuries from a bony standpoint for which ligamentous insufficiency may help determine whether operative stabilization is a consideration.
M2	Is used to designate a patient-specific comorbidity, which might argue either for or against surgery for patients with relative surgical indications. Examples of an M2 modifier include ankylosing spondylitis or burns affecting the skin overlying the injured spine.

Classification Nomenclature

Displacement injury of the segment T 8/9 with an incomplete burst fracture of T9, incomplete spinal cord injury, ankylosing spondylitis

Complete burst fracture of L1, neurologically intact, PLC status unclear



L1:B2; N0



Boston
Children's
Hospital



HARVARD
MEDICAL SCHOOL

CORTICES

ADVANCING EVIDENCE-BASED ORTHOPEDIC CARE

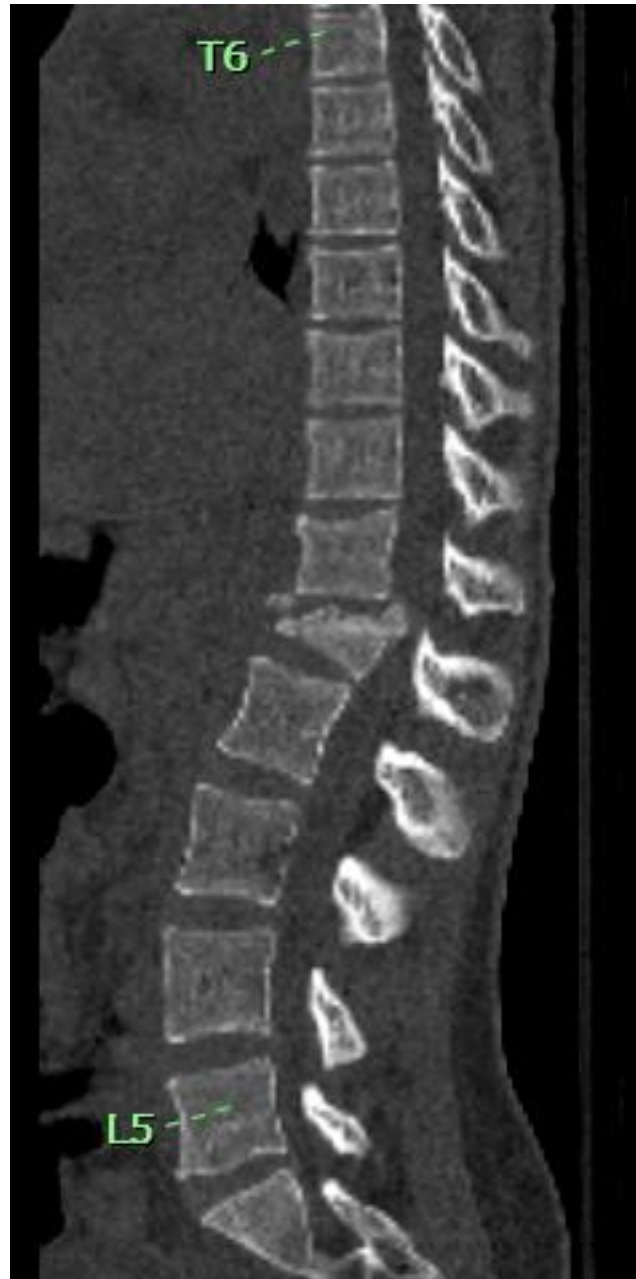Case 1:

TLICS
5

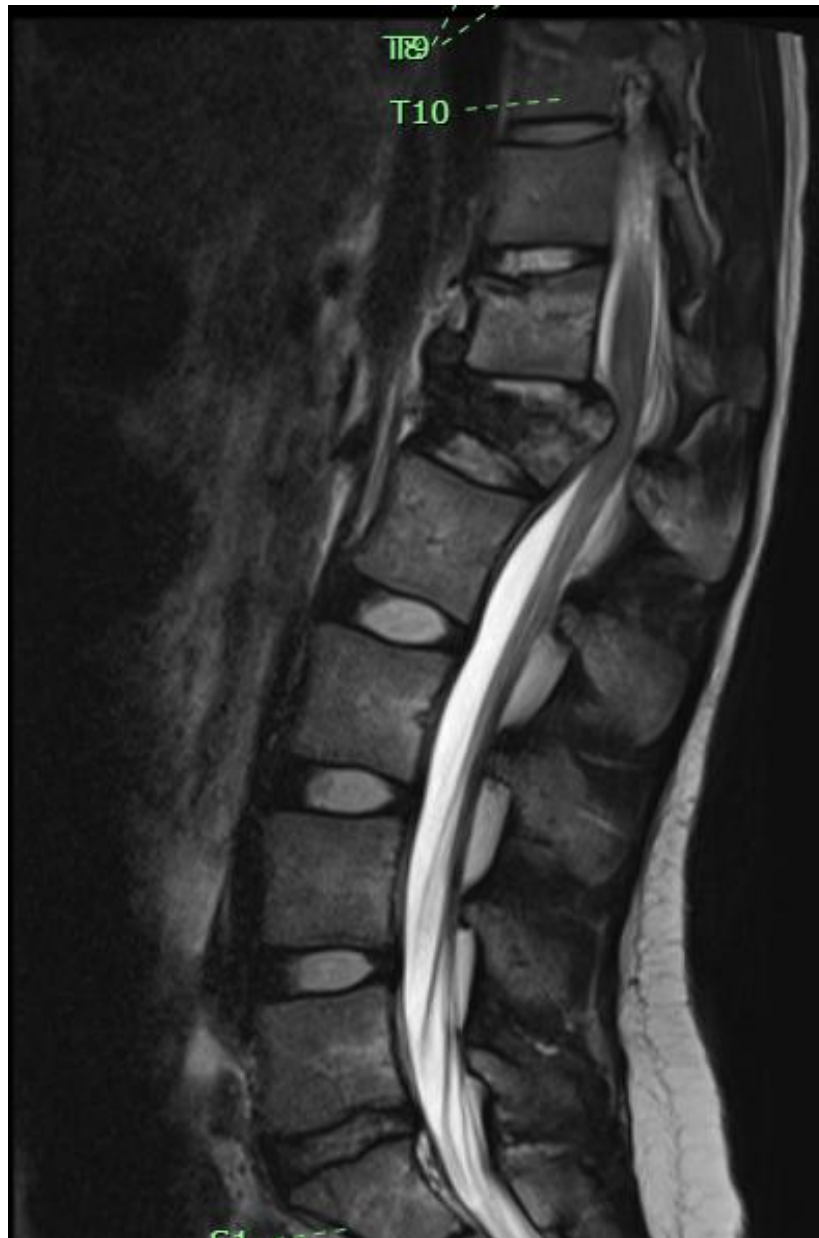TLICS 3 independent predictors				
1	Morphology immediate stability	<ul style="list-style-type: none"> - Compression - Burst ← - Translation/rotation - Distraction 	1 2 3 4	<ul style="list-style-type: none"> - Radiographs - CT
2	Integrity of PLC longterm stability	<ul style="list-style-type: none"> - Intact - Suspected - Injured ← 	0 2 3	<ul style="list-style-type: none"> - MRI
3	Neurological status	<ul style="list-style-type: none"> - Intact ← - Nerve root - Complete cord - Incomplete cord - Cauda equina 	0 2 2 3 3	<ul style="list-style-type: none"> - Physical examination
Predicts		<ul style="list-style-type: none"> - Need for surgery 	0 – 3 4 > 4	<ul style="list-style-type: none"> - nonsurgical - surgeon's choice - surgical

Case 2:

- 16 year old female
- Otherwise healthy
- Syncopal fall from 6 feet
- Urinary retention
- Saddle anesthesia

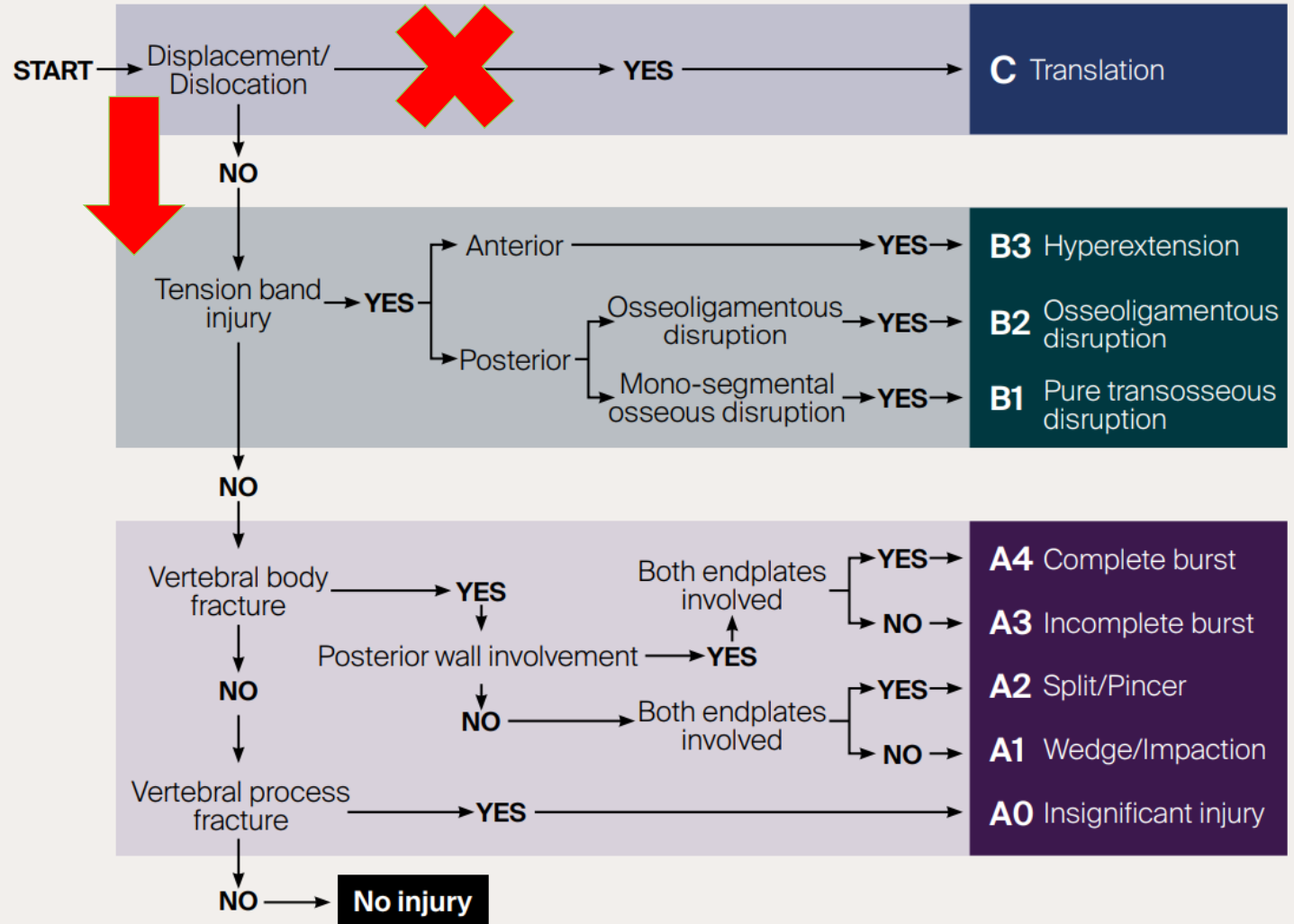


Case 2:



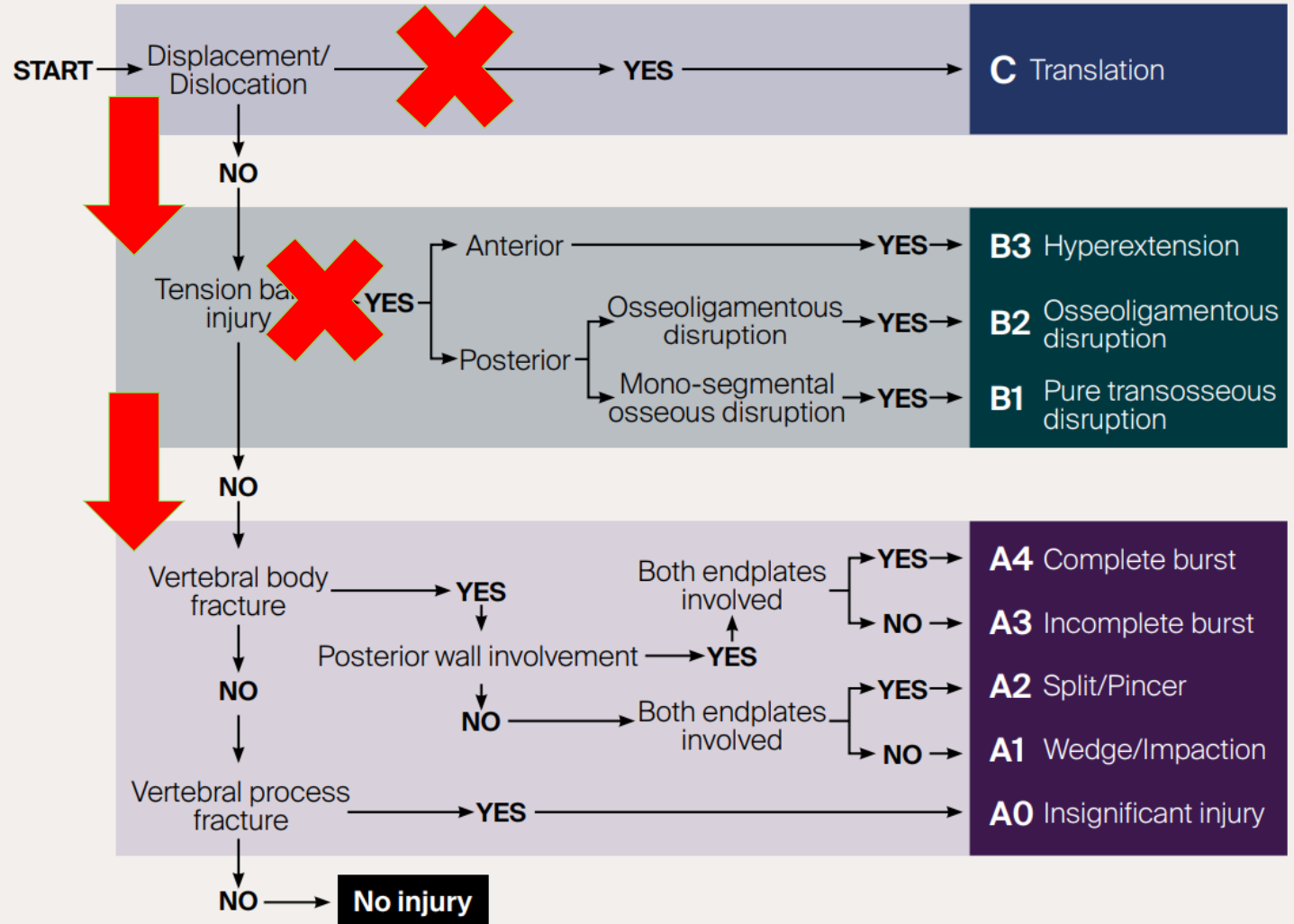
Case 2:

Algorithm for morphologic classification



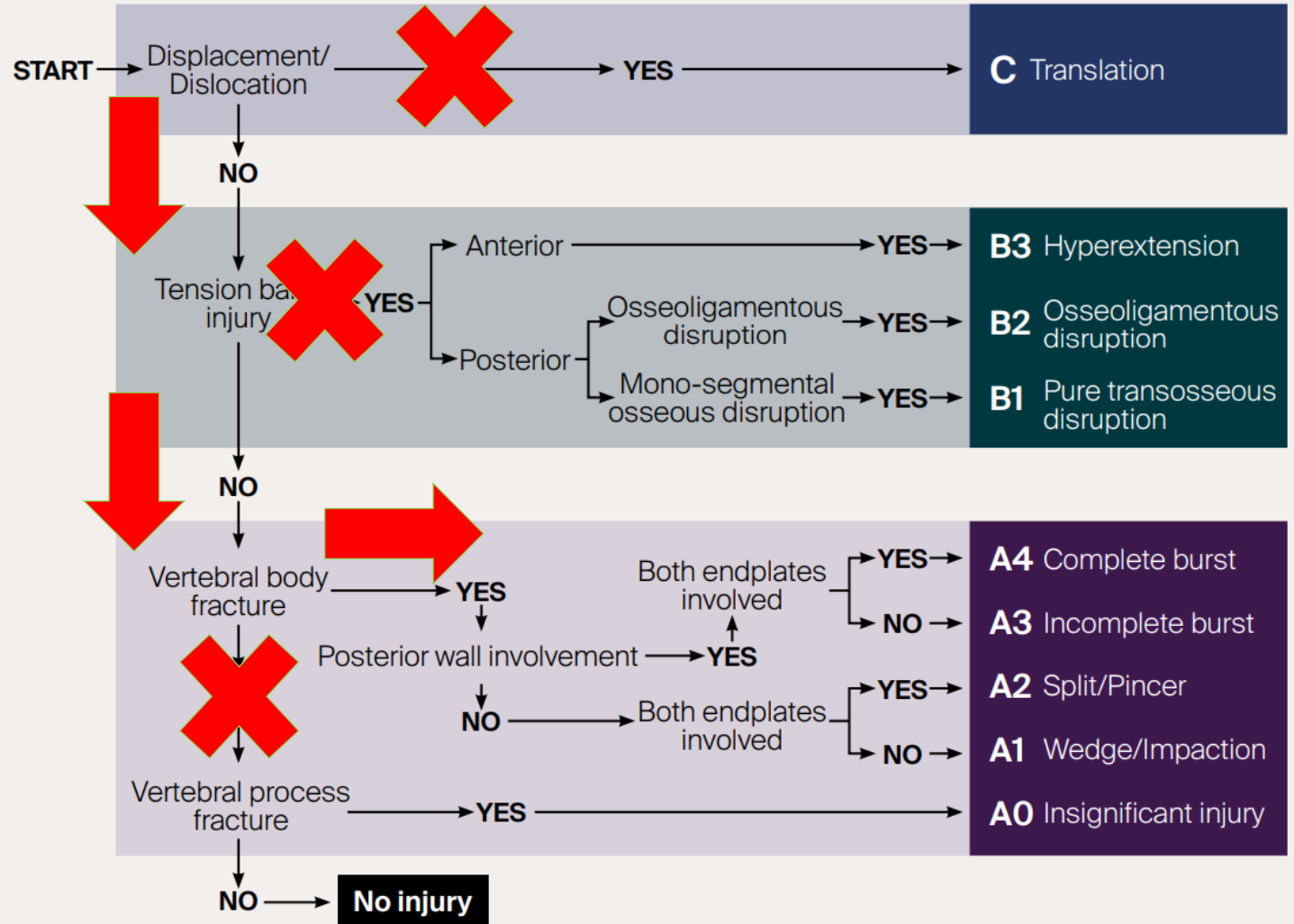
Case 2:

Algorithm for morphologic classification



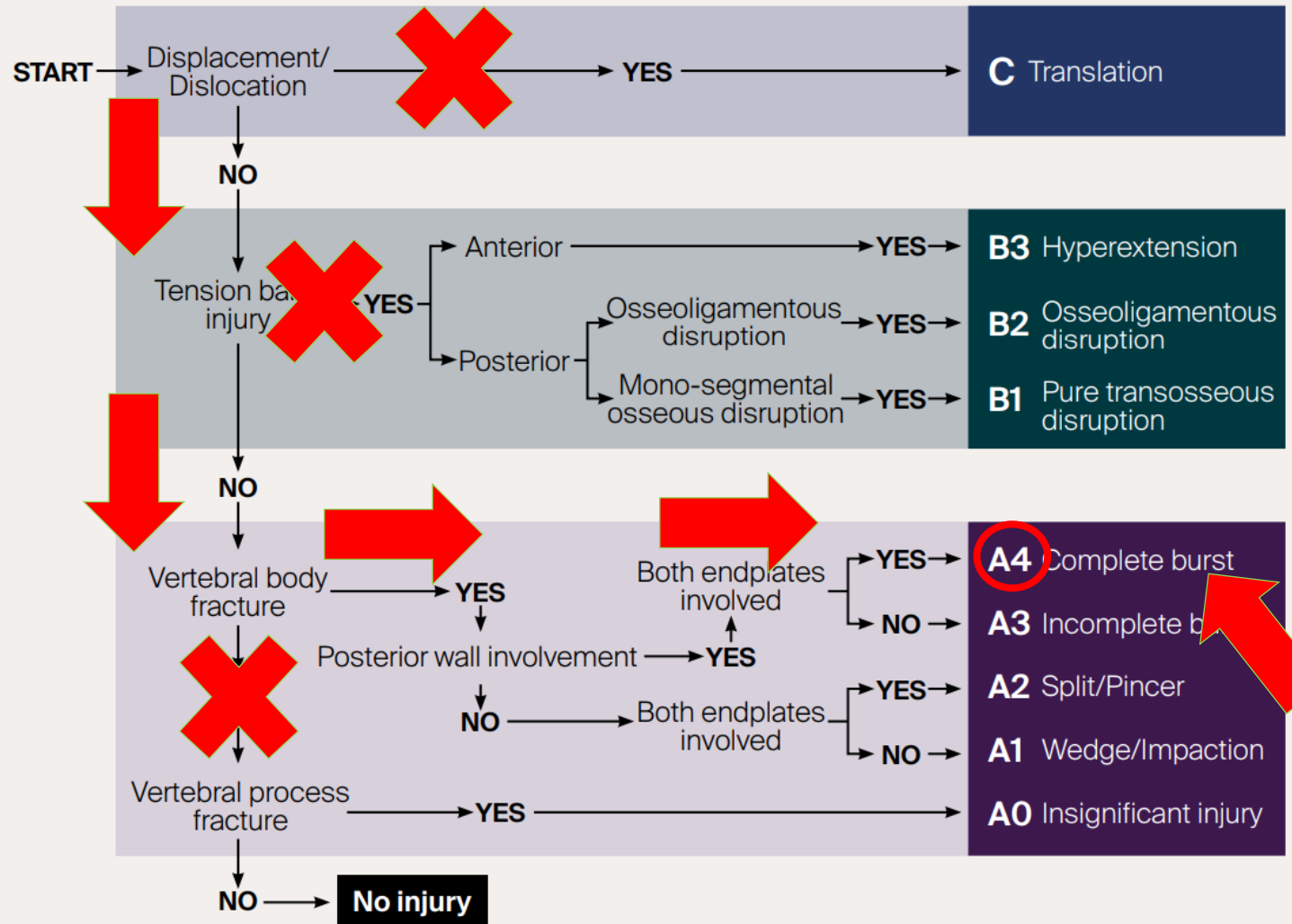
Case 2:

Algorithm for morphologic classification



Case 2:

Algorithm for morphologic classification



Case 2:

Neurology

Type	Neurological
N0	Neurology intact
N1	Transient neurologic deficit
N2	Radicular symptoms
N3	Incomplete spinal cord injury or any degree of cauda equina injury
N4	Complete spinal cord injury
NX	Cannot be examined
+	Continued spinal cord compression

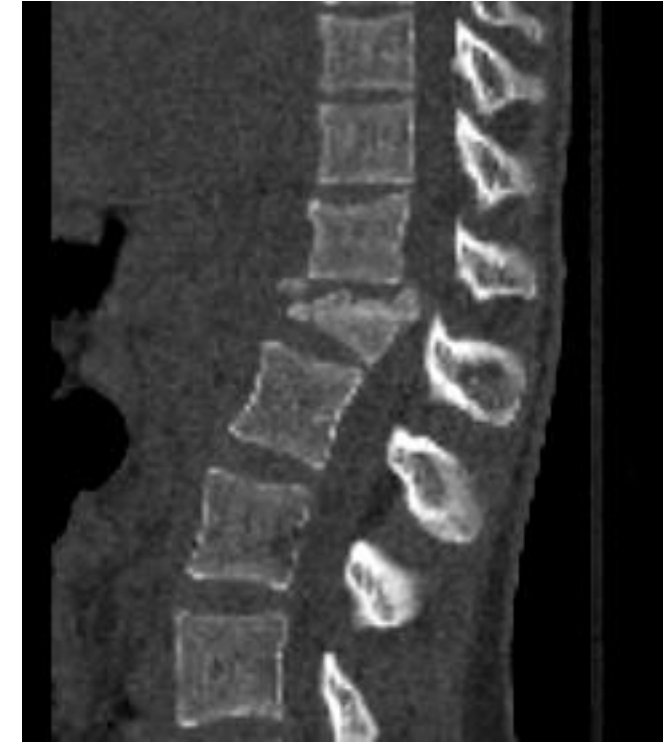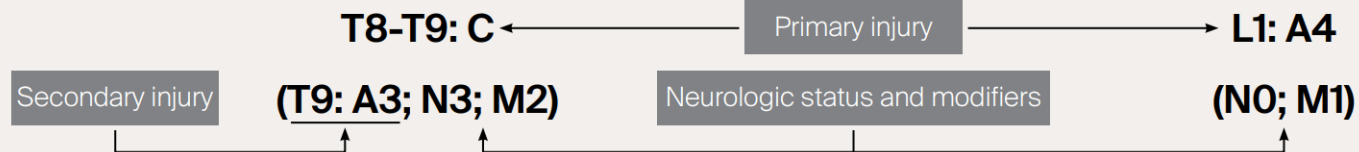
Modifiers

Type	Description
M1	This modifier is used to designate fractures with an indeterminate injury to the tension band based on spinal imaging with or without MRI. This modifier is important for designating those injuries with stable injuries from a bony standpoint for which ligamentous insufficiency may help determine whether operative stabilization is a consideration.
M2	Is used to designate a patient-specific comorbidity, which might argue either for or against surgery for patients with relative surgical indications. Examples of an M2 modifier include ankylosing spondylitis or burns affecting the skin overlying the injured spine.

Classification Nomenclature

Displacement injury of the segment T 8/9 with an incomplete burst fracture of T9, incomplete spinal cord injury, ankylosing spondylitis

Complete burst fracture of L1, neurologically intact, PLC status unclear



L1:A4; N3

Case 2:

TLICS 5

TLICS 3 independent predictors				
1	Morphology immediate stability	<ul style="list-style-type: none"> - Compression - Burst ← - Translation/rotation - Distraction 	1 2 3 4	<ul style="list-style-type: none"> - Radiographs - CT
2	Integrity of PLC longterm stability	<ul style="list-style-type: none"> - Intact ← - Suspected - Injured 	0 2 3	<ul style="list-style-type: none"> - MRI
3	Neurological status	<ul style="list-style-type: none"> - Intact - Nerve root - Complete cord - Incomplete cord ← - Cauda equina 	0 2 2 3 3	<ul style="list-style-type: none"> - Physical examination
Predicts		<ul style="list-style-type: none"> - Need for surgery 	0 – 3 4 > 4	<ul style="list-style-type: none"> - nonsurgical - surgeon's choice - surgical